3D Ec

Basic c

&

Clinica

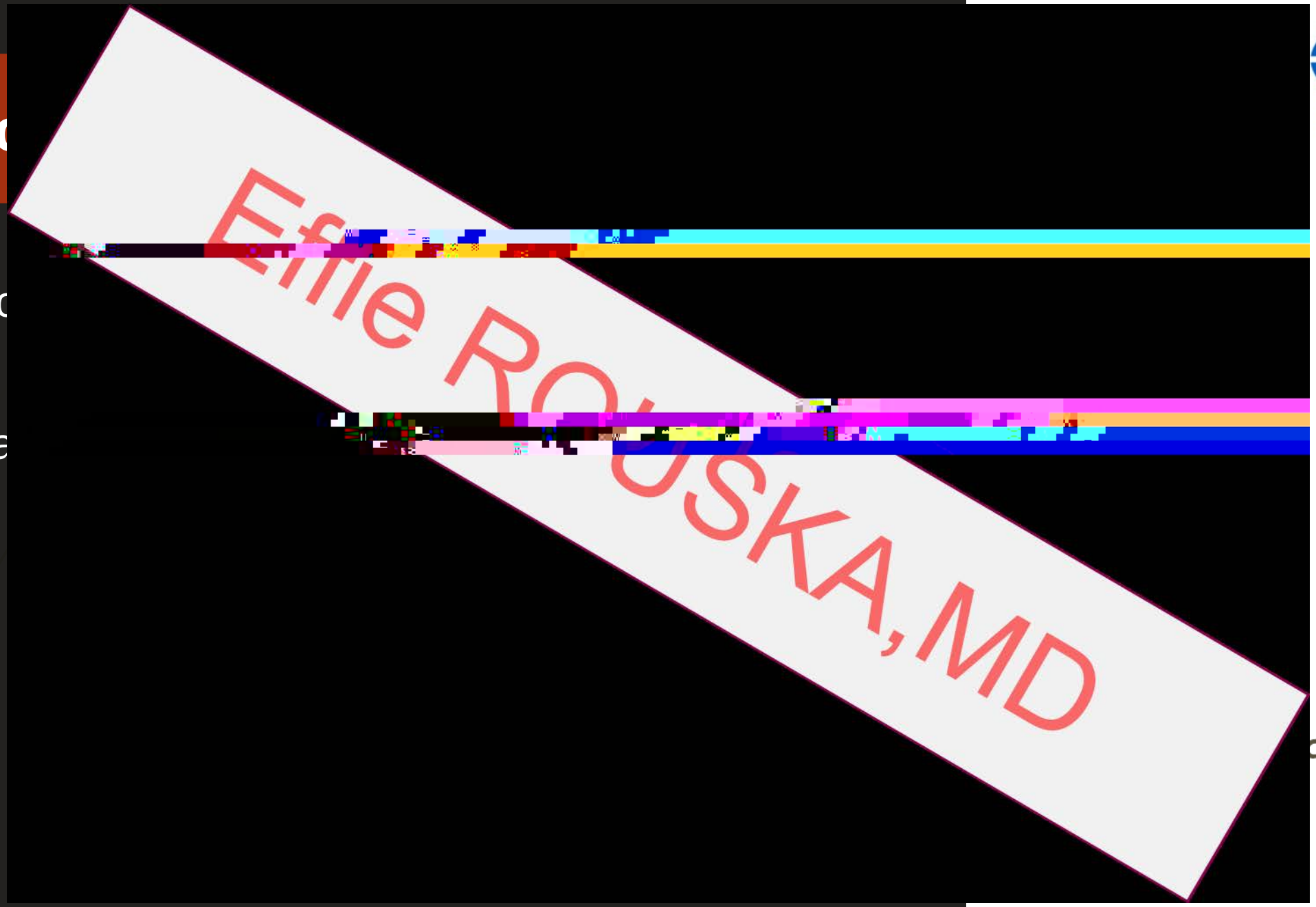

a, MD, PhD

ΠΑΝΕΠΙΣΤΗΜΙΑΚΟ ΓΕΝΙΚΟ
ΝΟΣΟΚΟΜΕΙΟ ΠΑΤΡΩΝ
"ΠΑΝΑΓΙΑ Η ΒΟΗΘΕΙΑ"

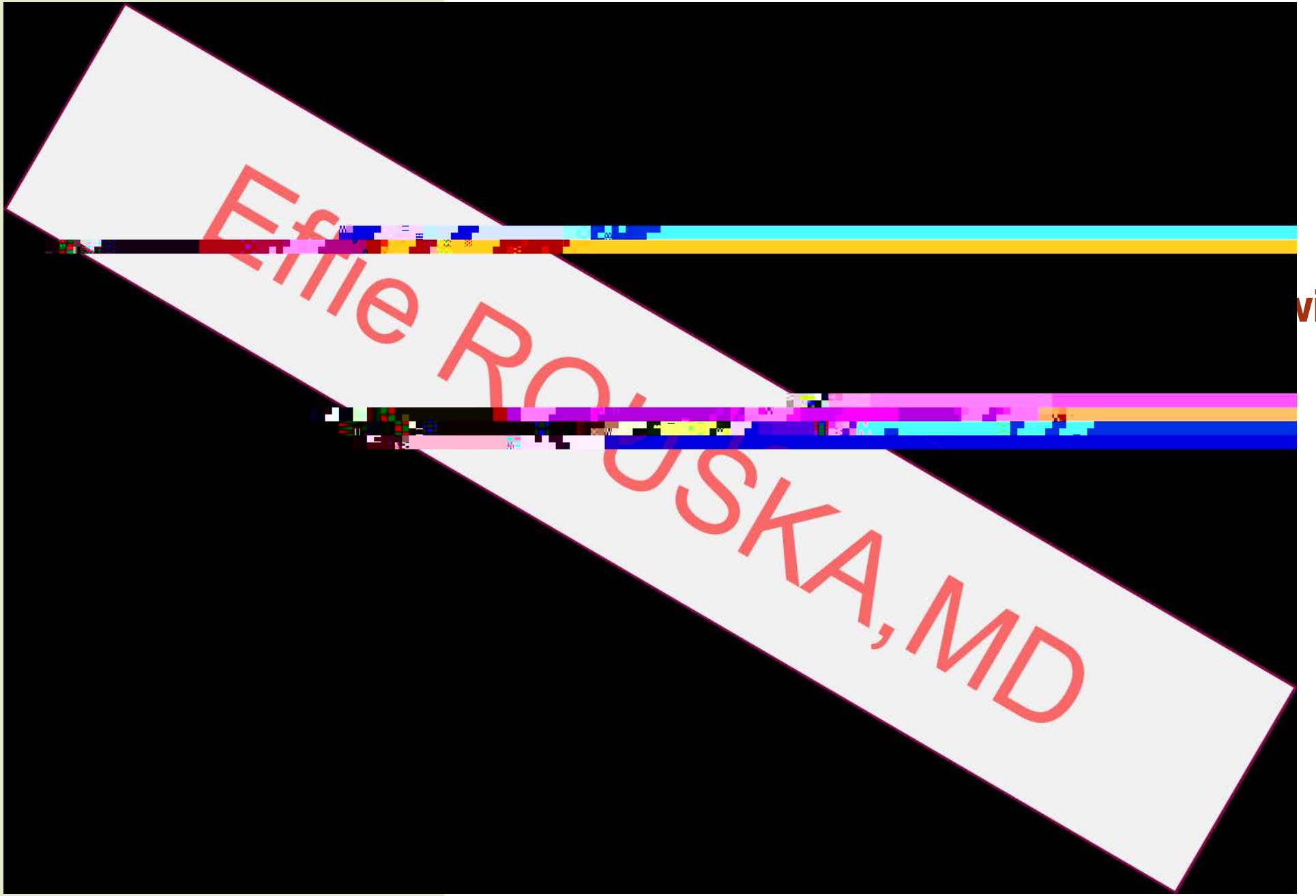

with

Once upon a time (1803-1853)

About Christian Dopp



Effie ROUSKA,MD

The Evolution of 3D Cardiology Transducers

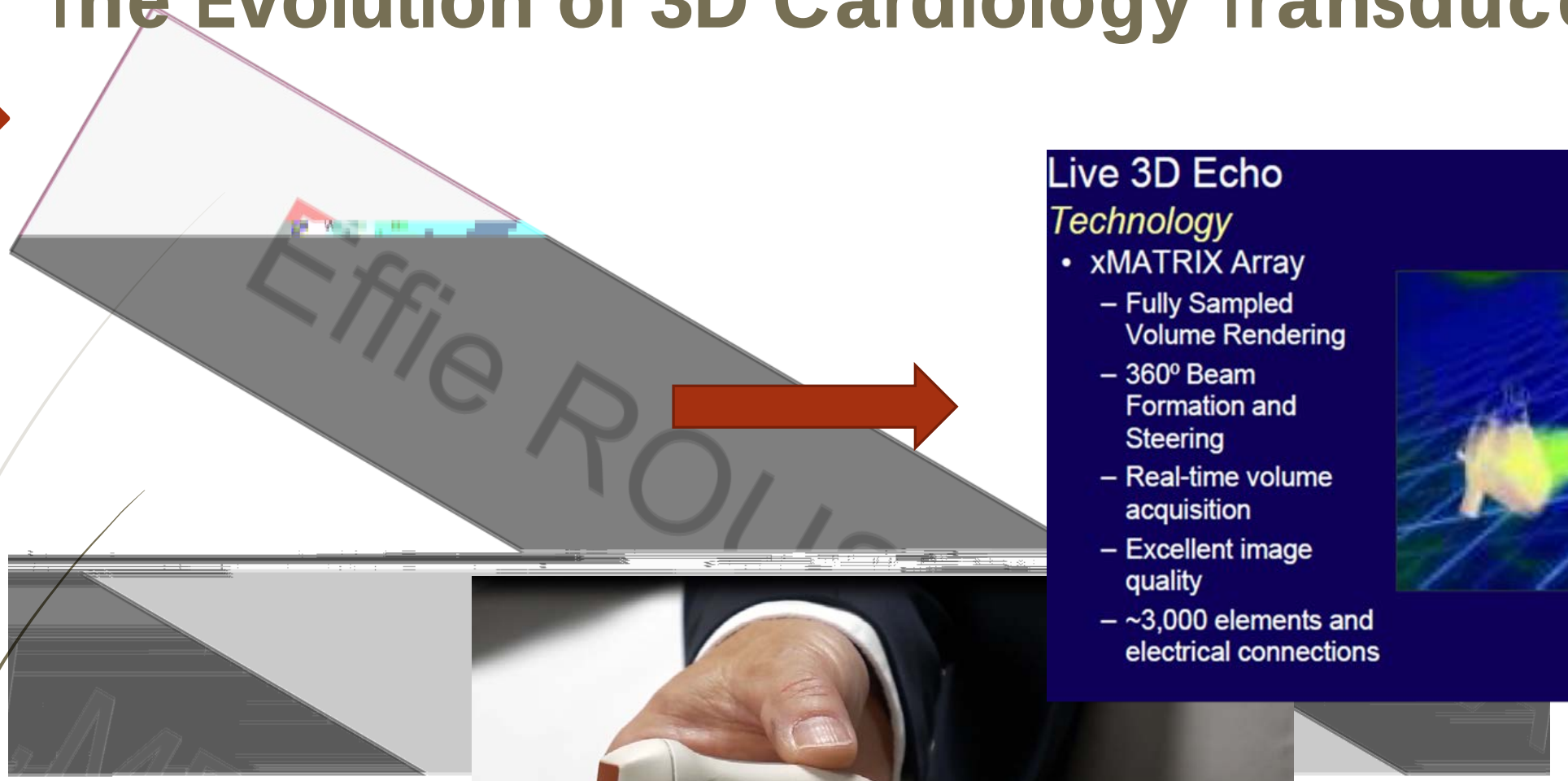

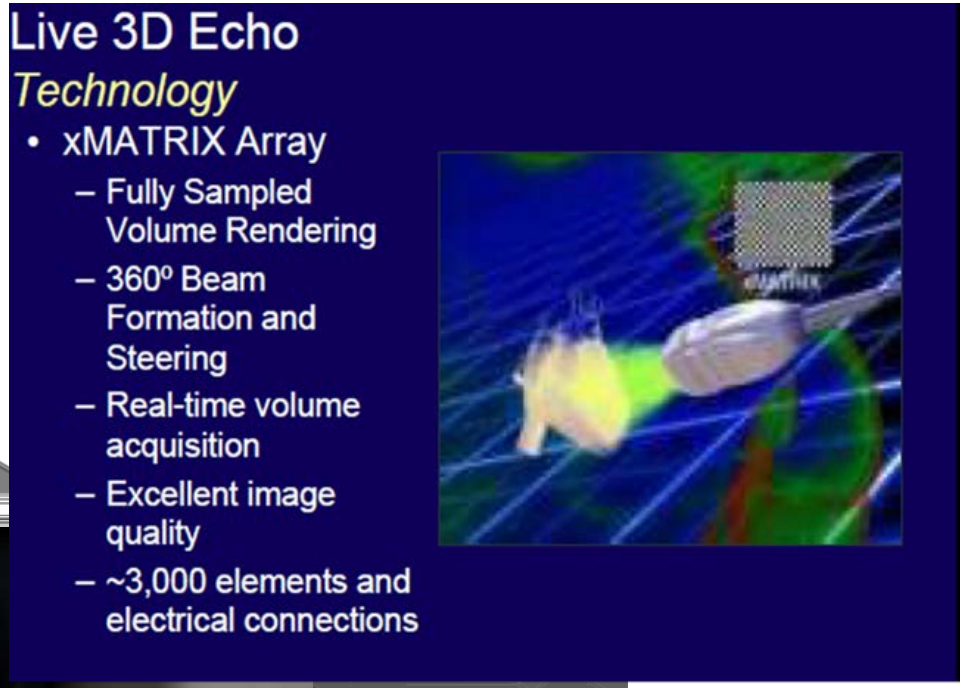

Full matrix array transducer

(2-4MHz for TTE,
5-7MHz for TOE & pediatric)

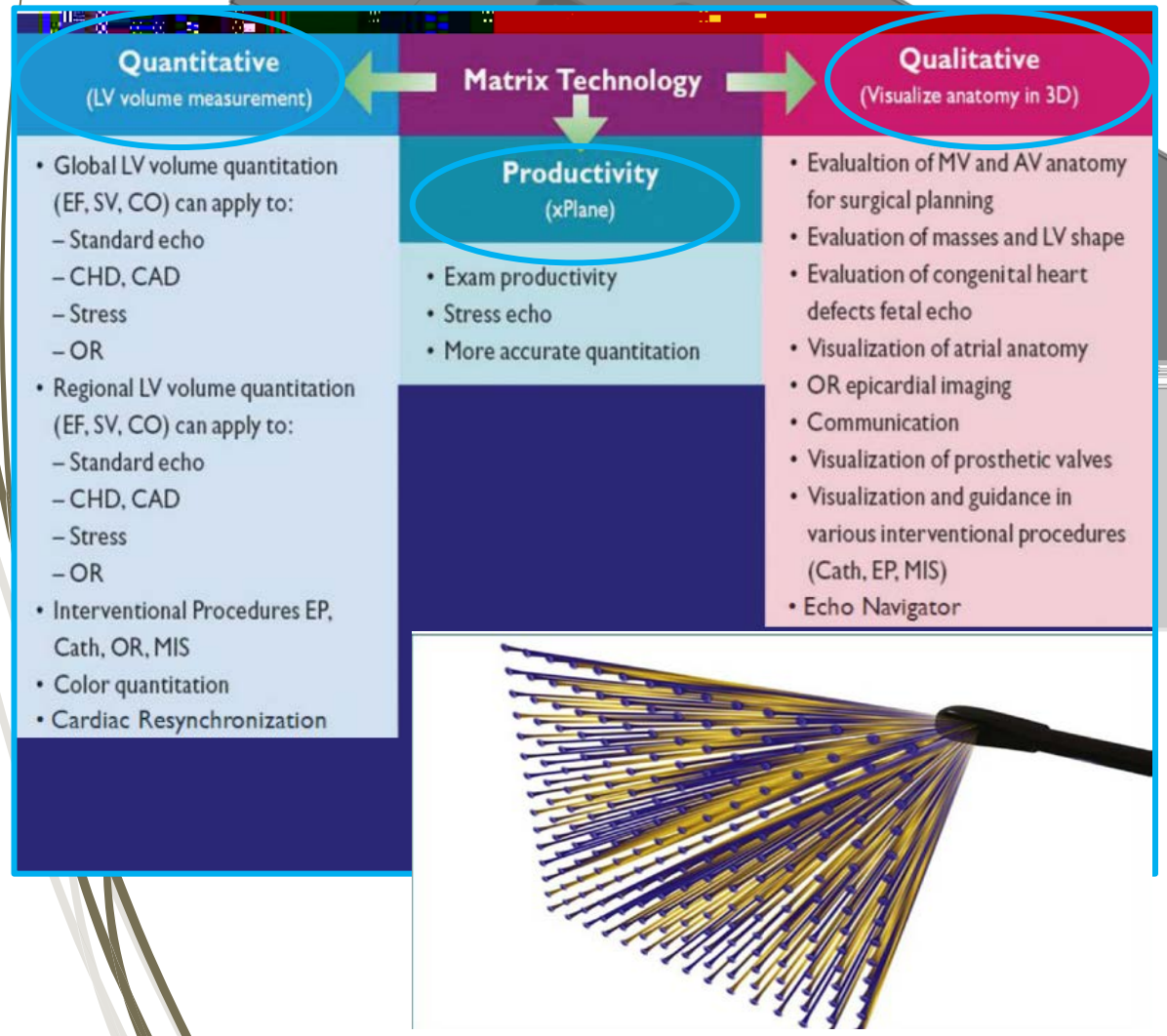



- Schematic drawing of a full matrix array transducer were about 3000 acoustically indepepndent piezoelectric elements are arranged in row and columns and used to steer the beam electronically. This matrix arrangement of piezoelectric elements allows their phasic firing to produce and ultrasound beam that can be steered in vertical (axial), lateral (azimuthal) and antero-posterior (elevation) directions in order to acquire a volumetric (pyramidal) data set.

Effie ROUSKA,MD

J Am

GUID

Reco
Acqu

Three
2012

Effie ROUSKA,MD

merican Society of
chocardiography
Ultrasound Specialists

r Chamber
om the American
's Guidelines and
d the Chamber
eveloped in
pean Association
Branch of the
Cardiology

are: Roberto M. Lang, MD, FASE,
ux, MD, Frank A. Flachskampf, MD,
Picard, MD, Mary J. Roman, MD,
SE, Scott D. Solomon, MD,
n Sutton, MD, FASE,
MD

2017

"With the
invasive,

emerging

knowled

familiar w

able to c

and perf
diseases

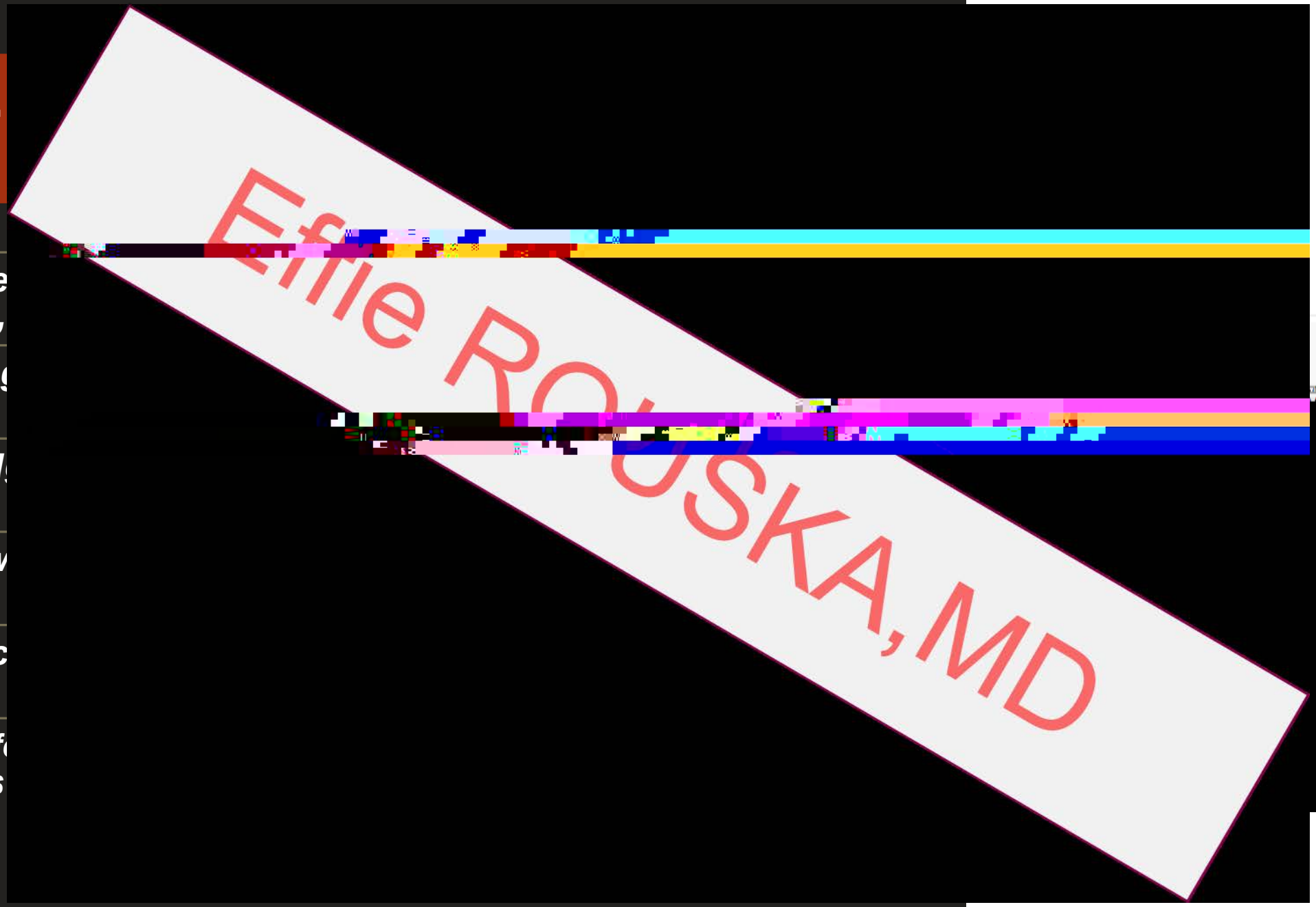

15 vps / 120 mm
Effie ROUSKA,MD

tion

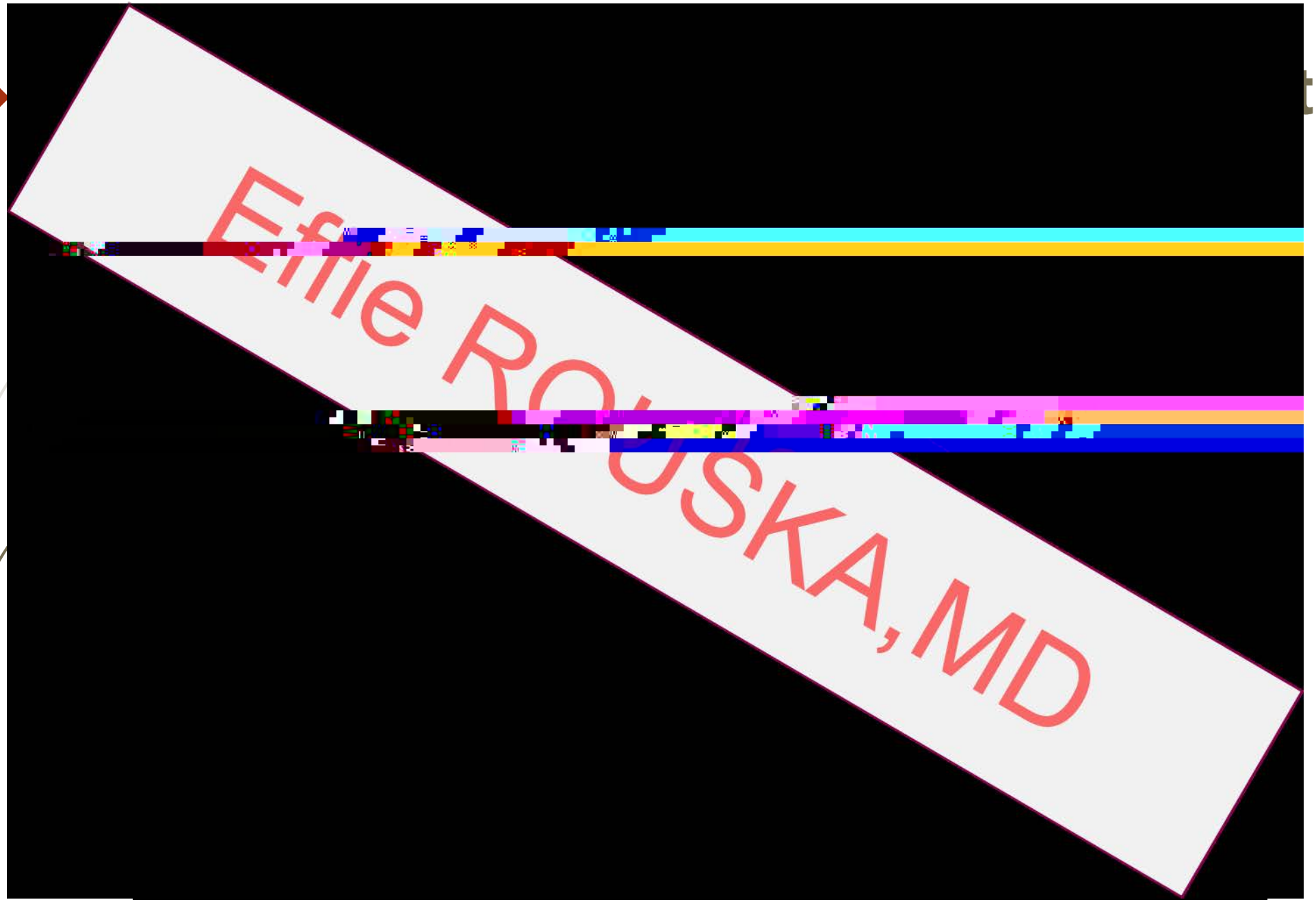

image

physics)

tch

each

Effie ROUSKA, MD


Effie ROUSKA,MD


Effie ROUSKA,MD

Effie ROUSKA,MD

Rate)

Relatio
sector s

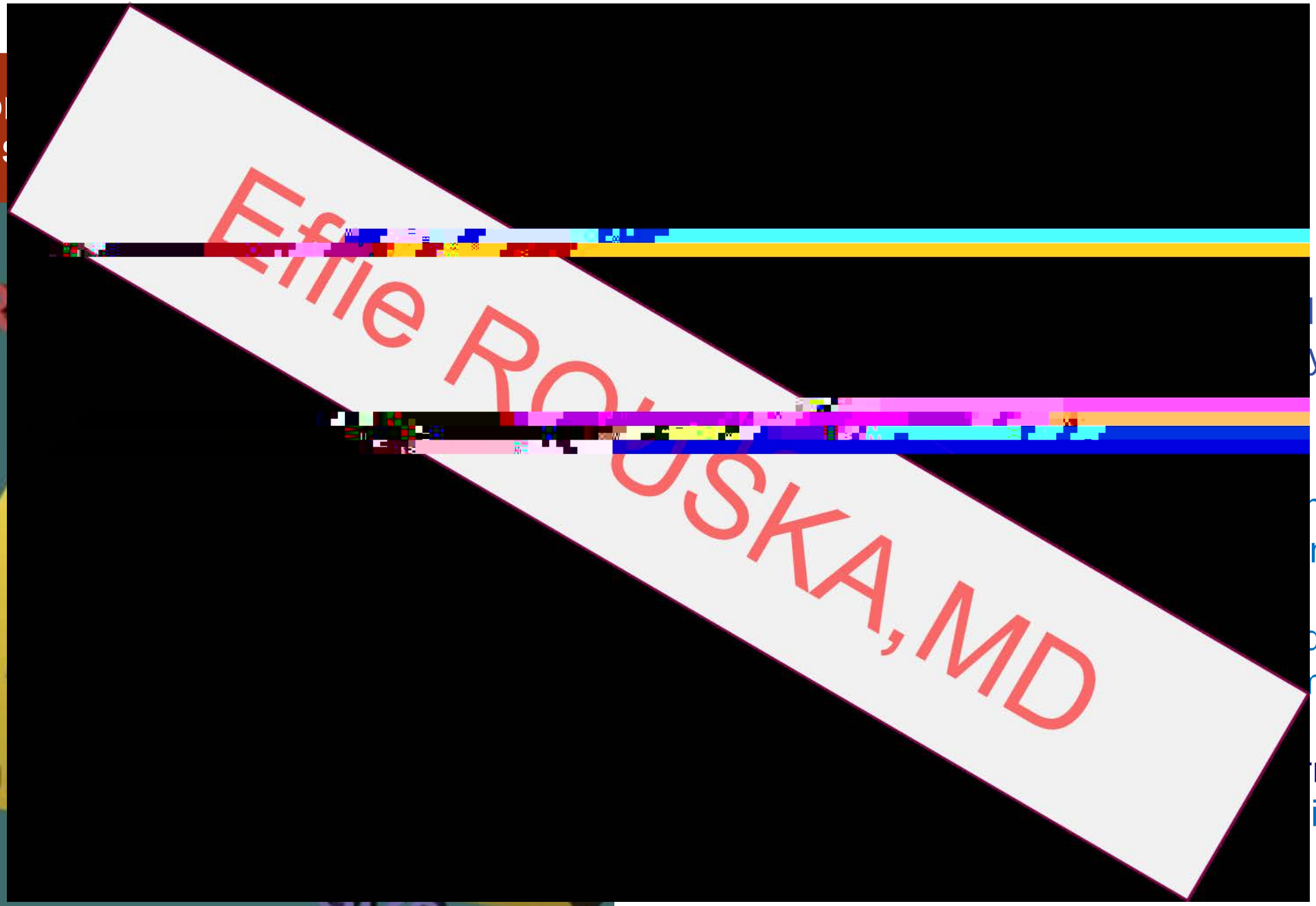

described
y **the**

ne size at
nstant

des to
naller

rminant of
ion but

Temporal vs Spatial Resolution

Effie ROUSKA,MD

Effie ROUSKA, MD

3D

- **Depth of 16c**
- **2D** (90 scanl
- **3D** (2400 sca

➨ **How to ir**

- Receiv

(parallel pro

- Decre
- Acquire data over multiple cardiac cycles (4-7) and built

Effie ROUSKA, MD

Effie ROUSKA,MD

lity

Trade
in 3D
Acqu

Effie ROUSKA,MD

n ideal 3D image. (B)
poral resolution. (C)
ial resolution. (D) For
enhanced sector size, the trade-off is a decrease in spatial and temporal resolutions.

nti-clockwise

(front and behind)
perspective for the

vithout movement of

ompare 2 structures

A uniq
is the c
in any

Rotatio

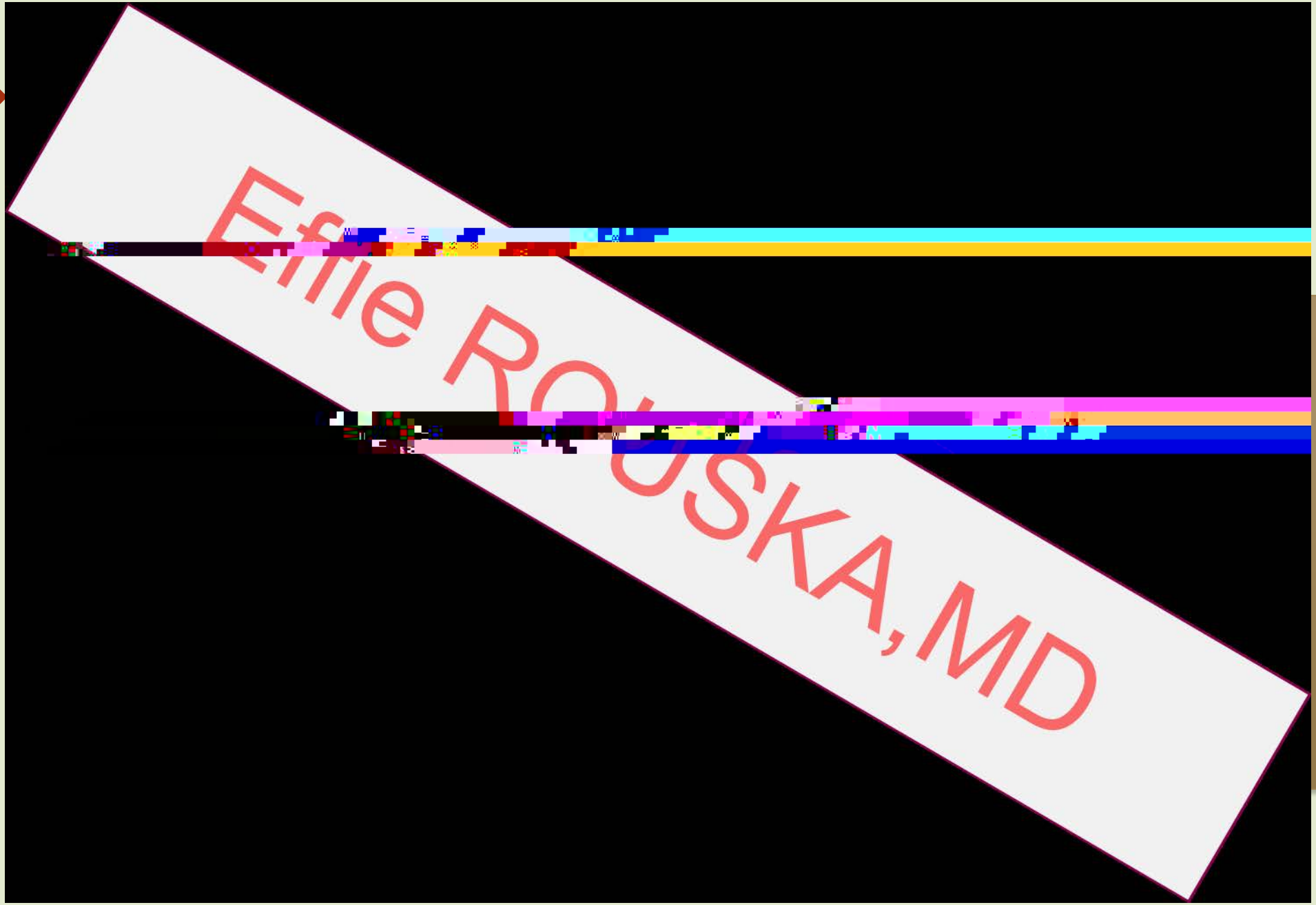
Effie ROUSKA, MD

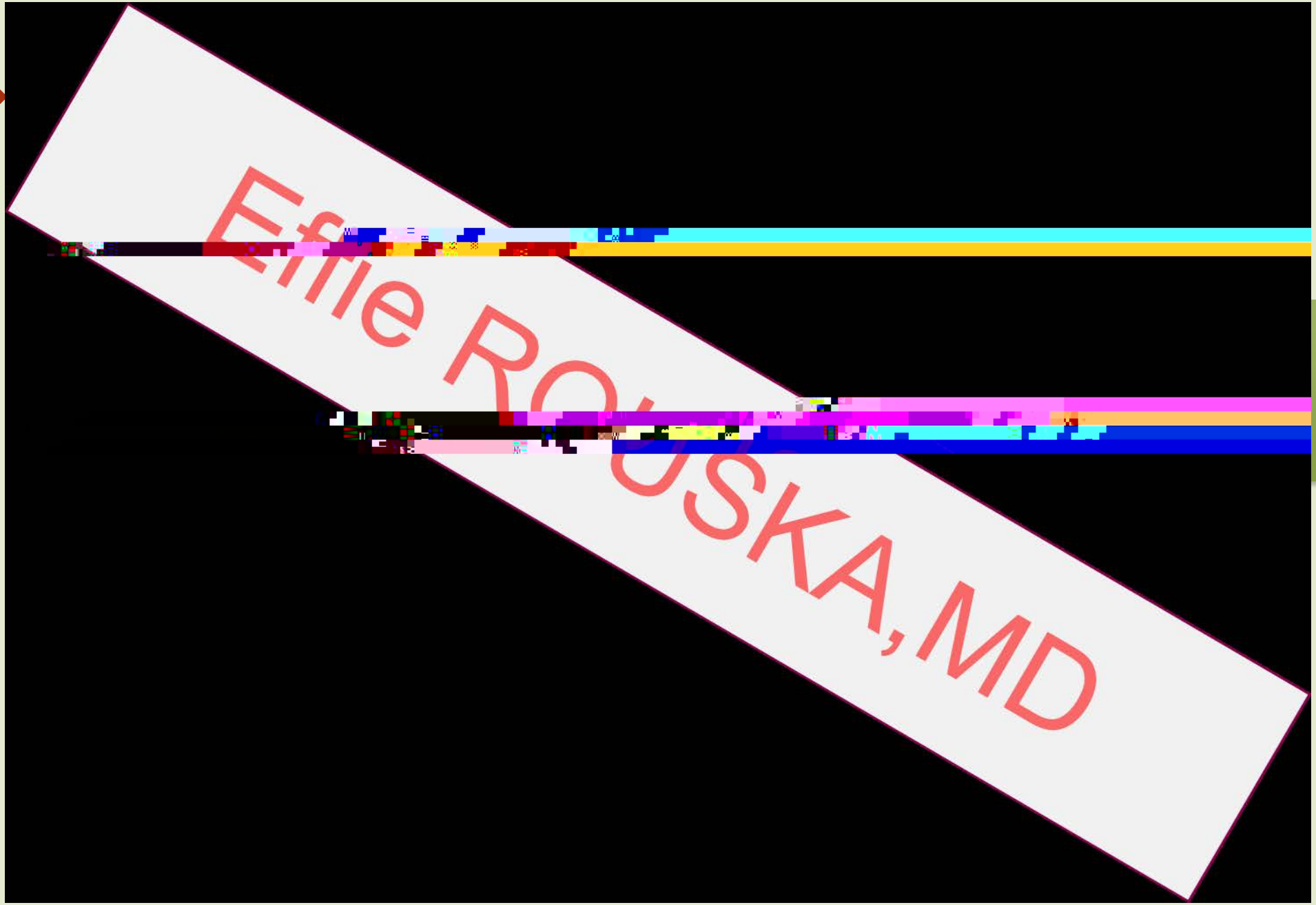
Effie ROUSKA,MD

e

ound

ace

eeping

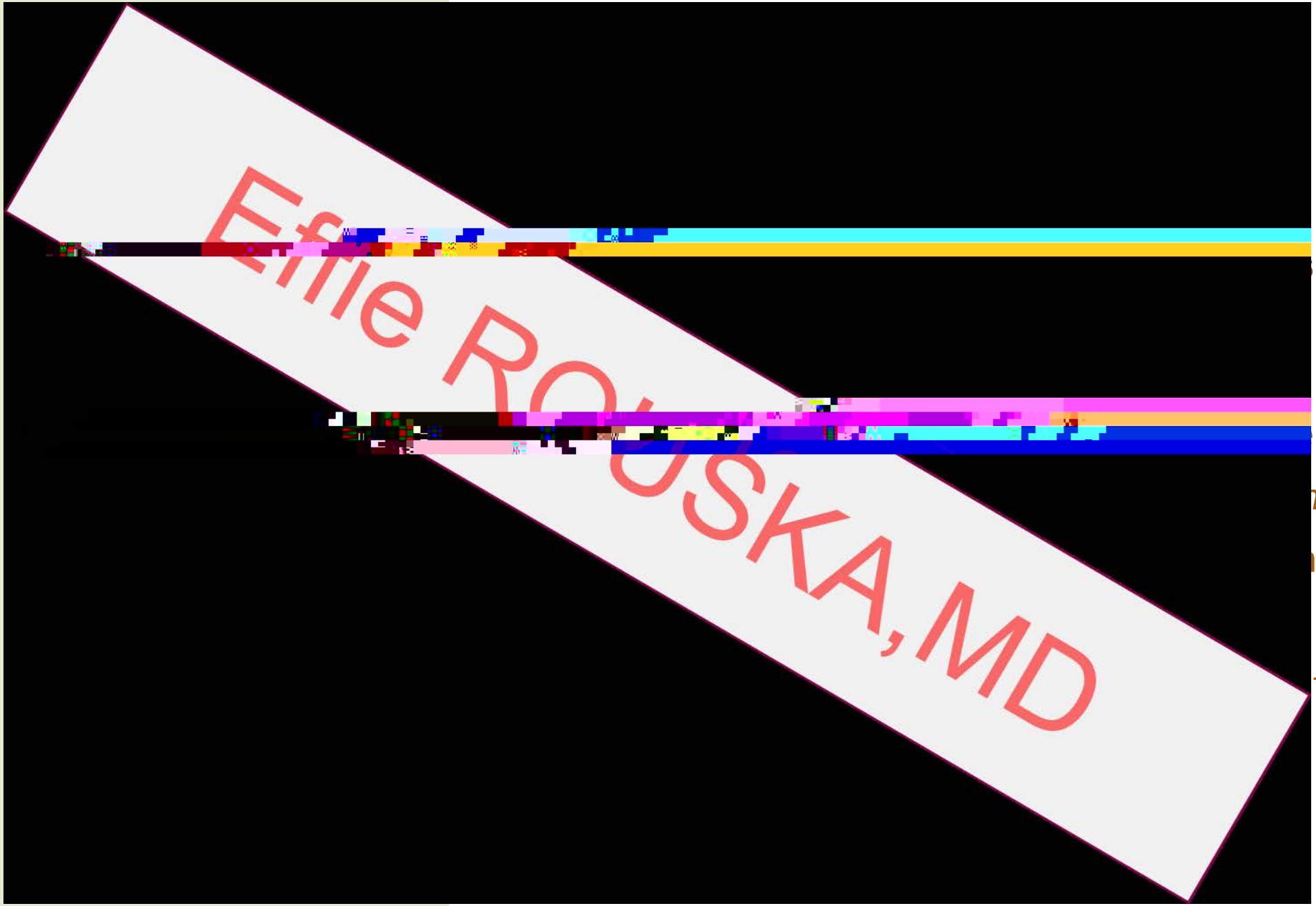

triggering)

as for 2D)

tting

noise)

es

full volume)


Effie ROUSKA,MD

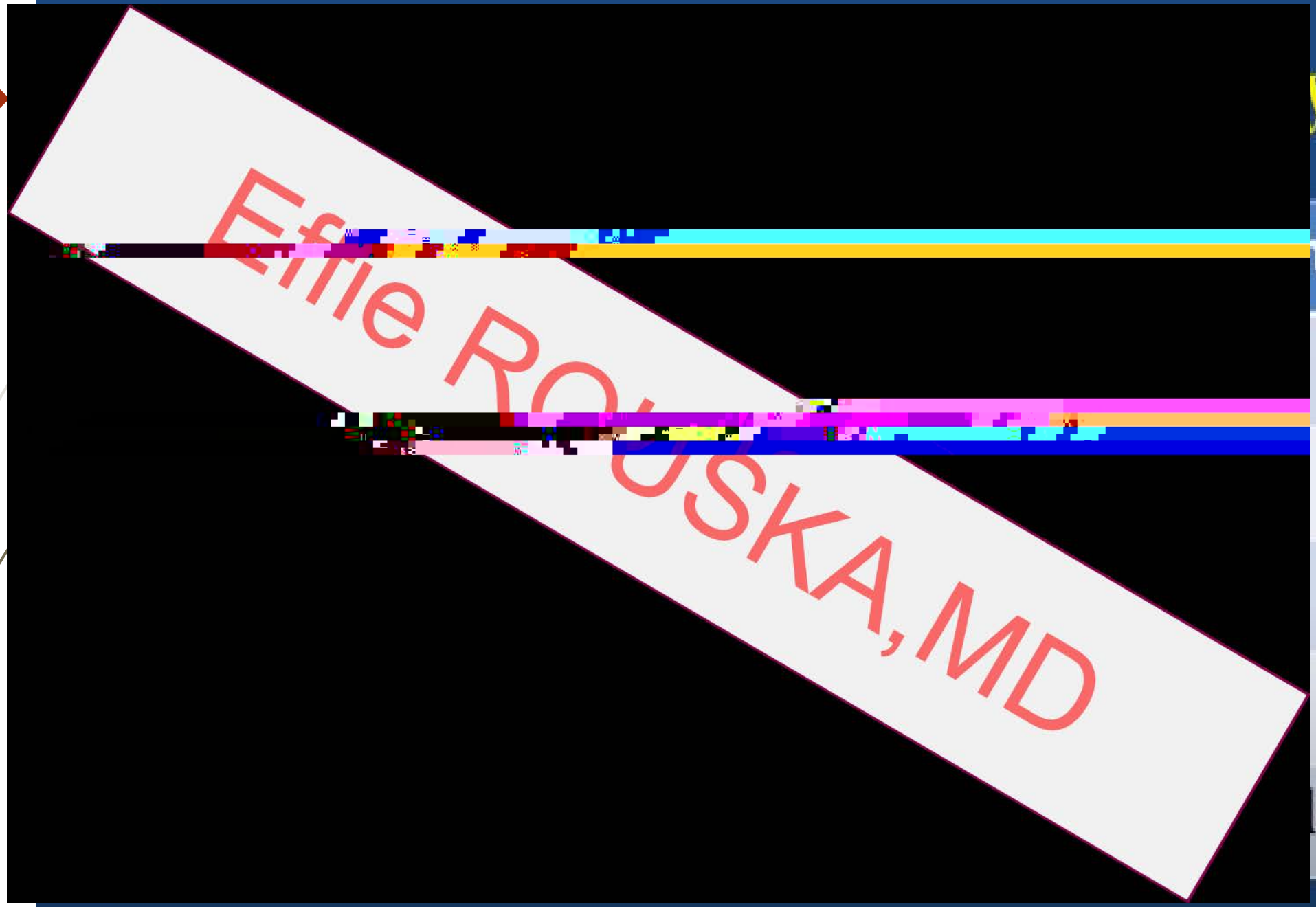
Effie ROUSKA,MD

Effie ROUSKA,MD



Effie ROUSKA,MD


+30°
-30°

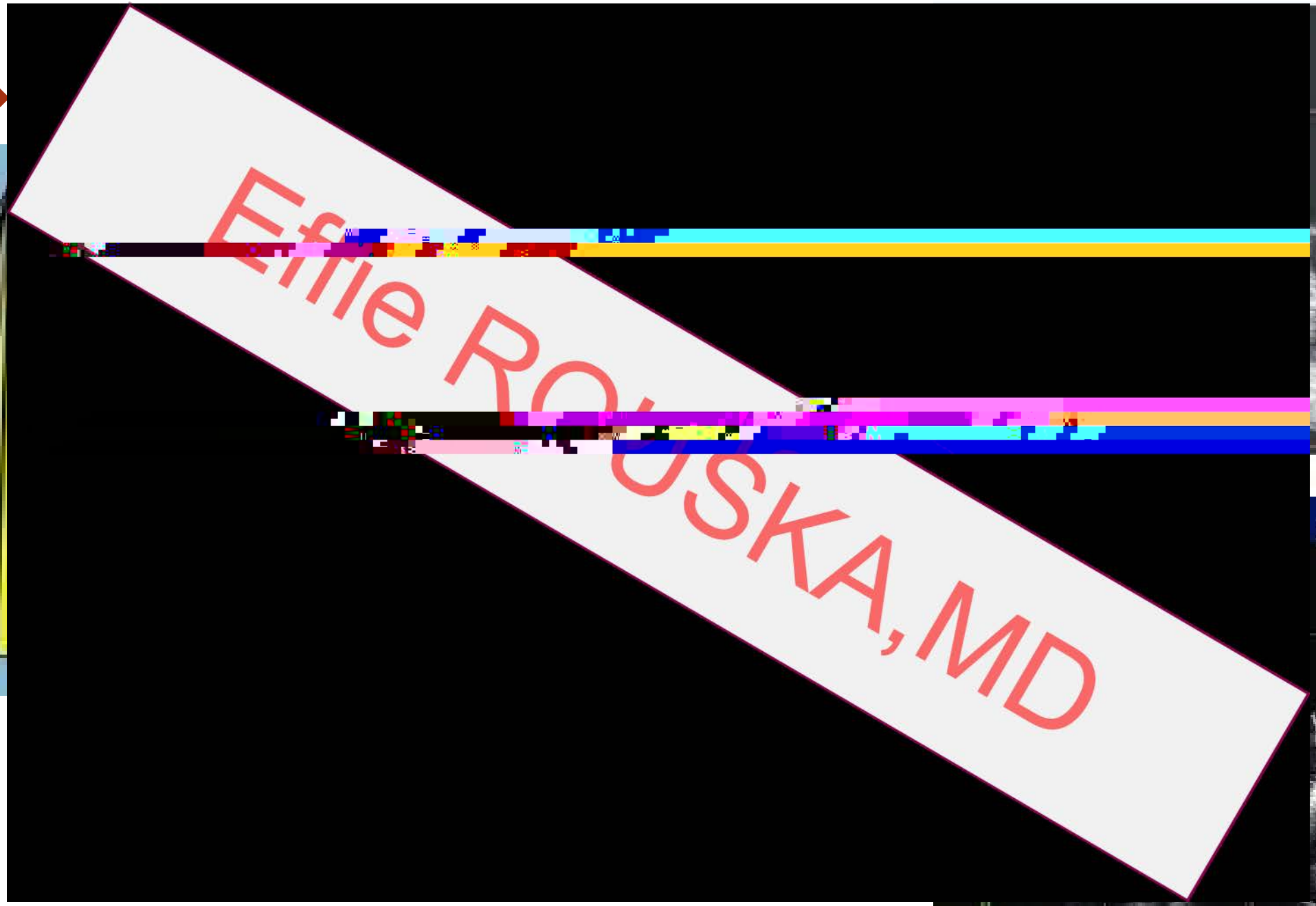
Effie ROUSKA,MD

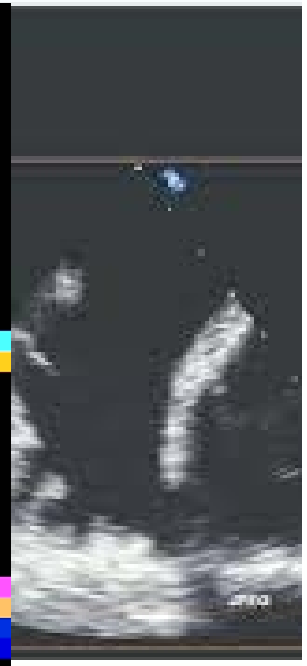

TI:0.1 MI 0.6
X7-2t/Adult
67 bpm

Effie ROUSKA,MD

Va

Us

X

Effie ROUSKA, MD

lution

Ad
Dis

X F

on when
)

a 3D probe)

Effie ROUSKA, MD


MI:1.1
X4
25 JAN 2006
A/5/H5
NIKAIA GEN.HOS
A'CARDIOL.DEPT
Full analyse
1:29:45
3D GAIN 72
3D COMP 50
74BPM
13CM
22HZ
2.0
4.0
5.25
SEC
Effie R
A,MD

Effie ROUSKA,MD

Va

Us

Liv

Ad

Dis

Liv



ith

Mer
Der

Nar
Live
(30-

motion


Effie ROUSKA, MD

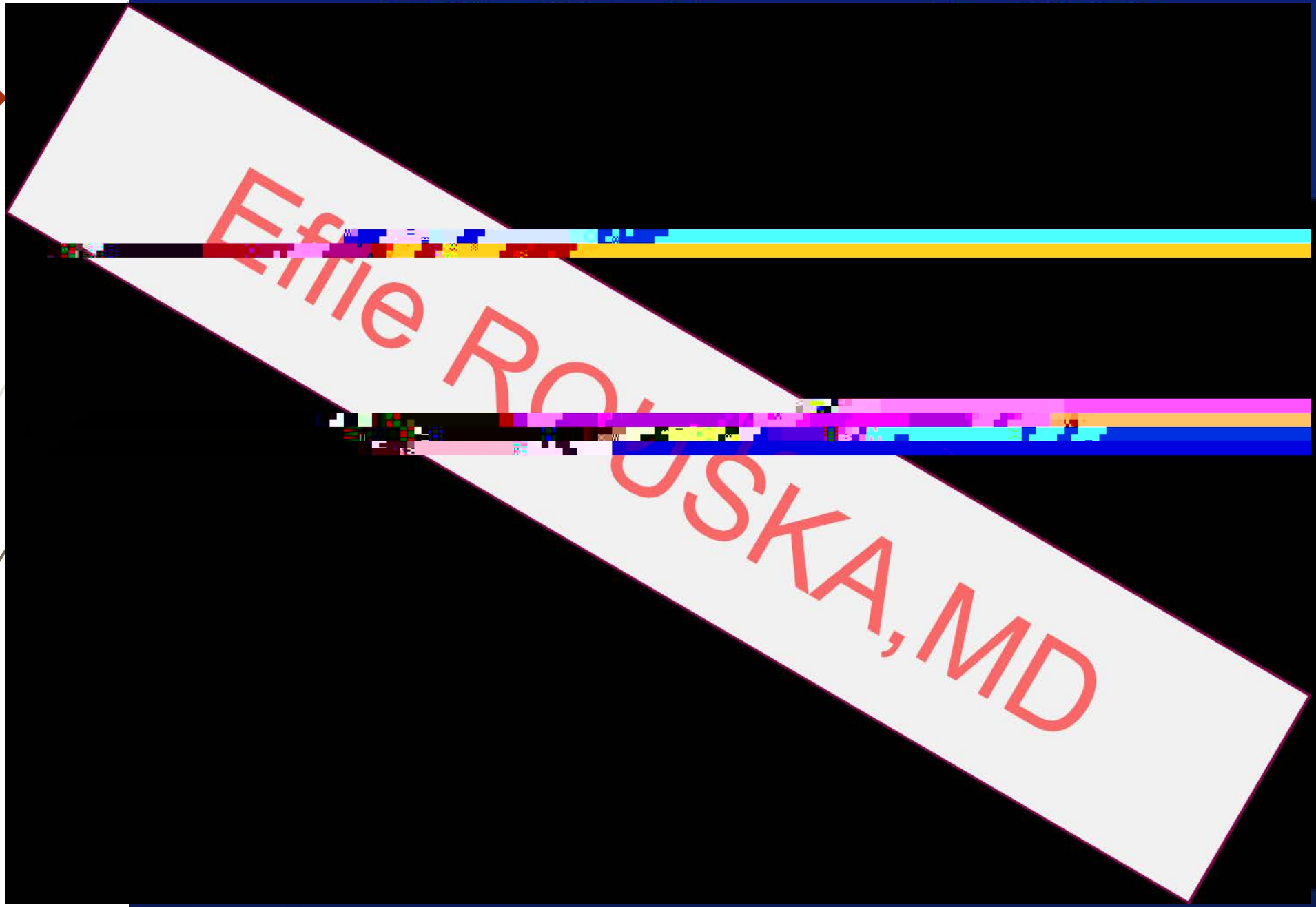
Effie ROUSKA,MD

Effie ROUSKA,MD

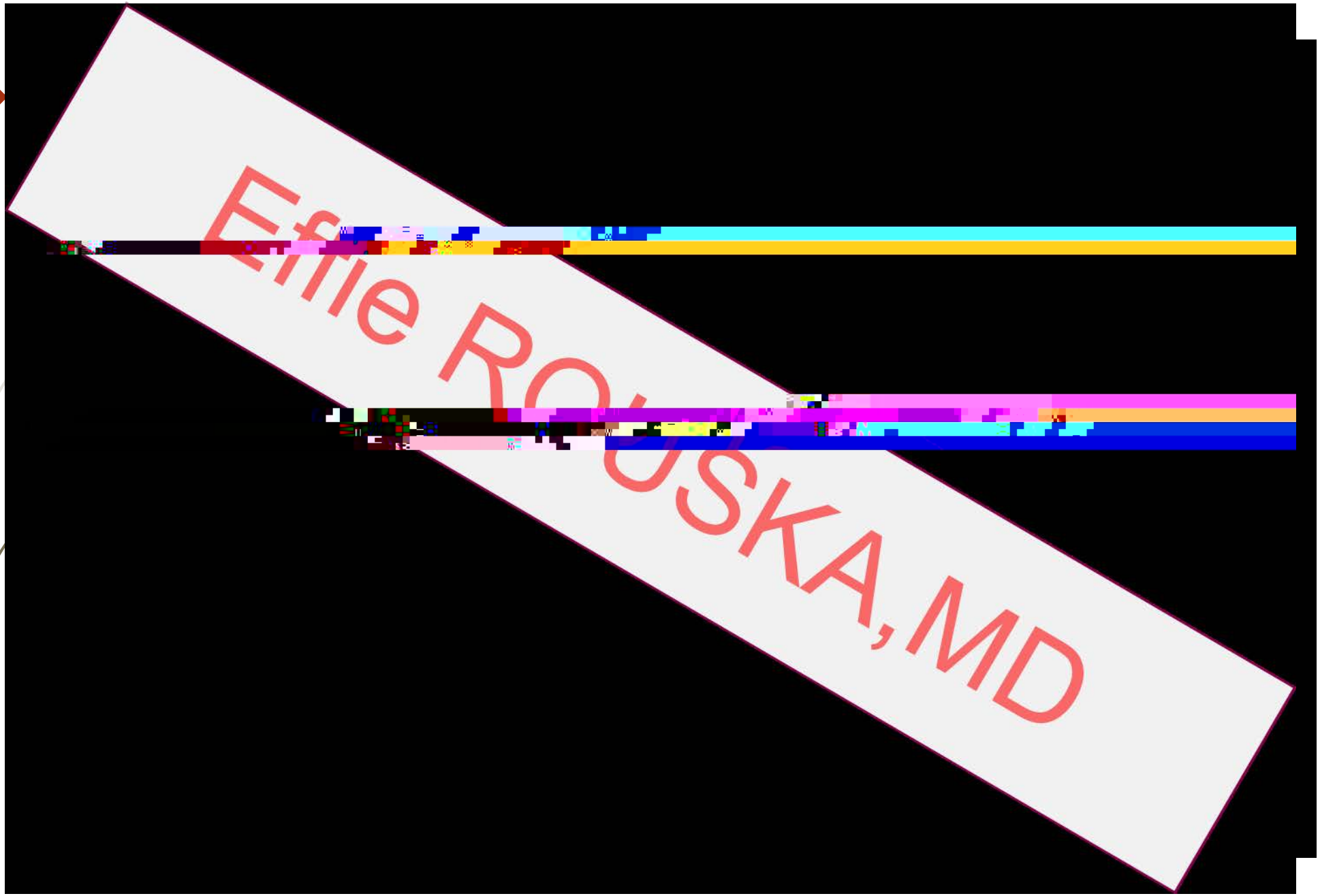
Effie ROUSKA,MD

n of :

, flail,

Val

3D

re

of

ce size

evice

Effie ROUSKA,MD

Ad

Dis

3D

ve

red to

IV. FULL VOLUME

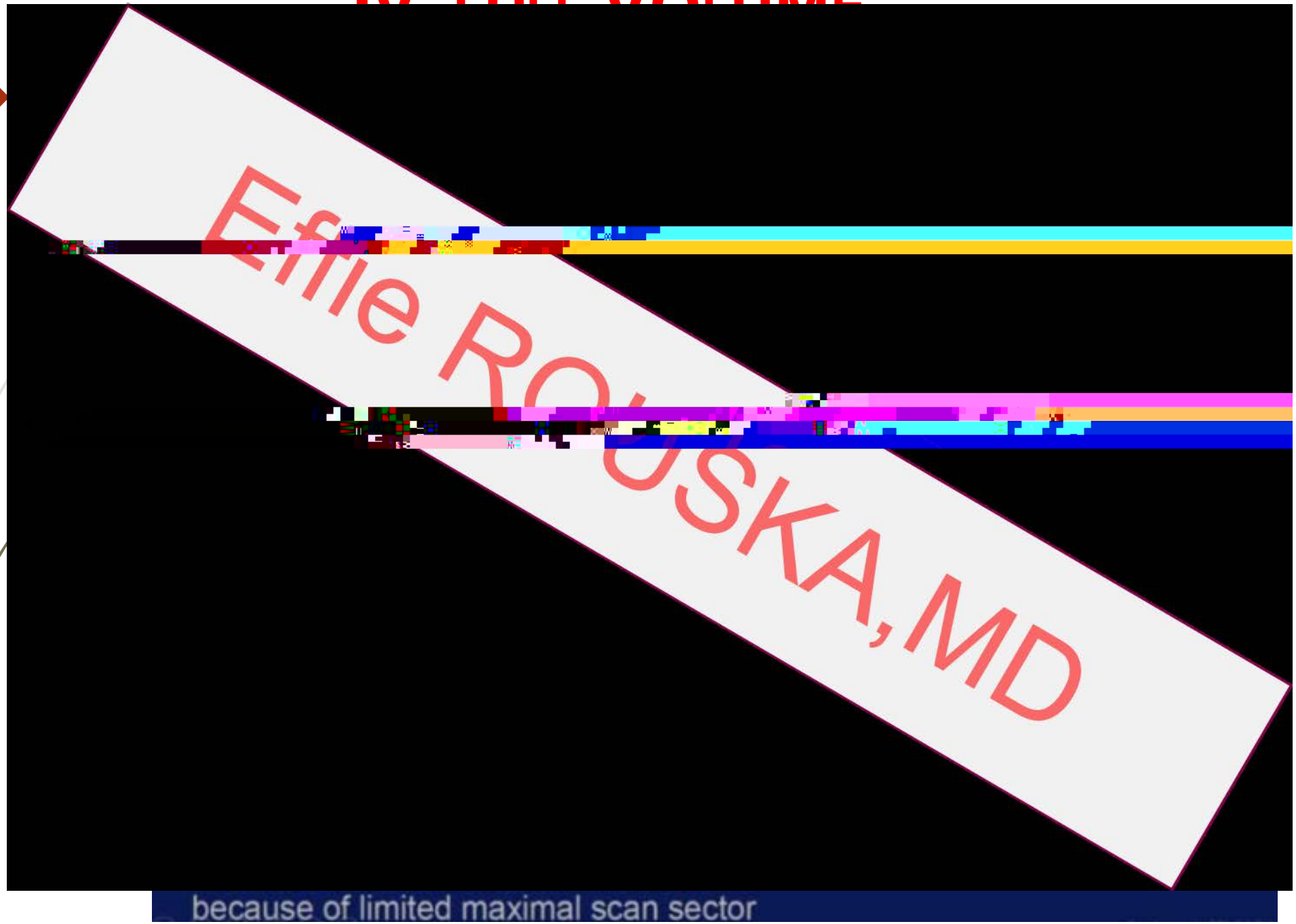

IV. FULL VOLUME

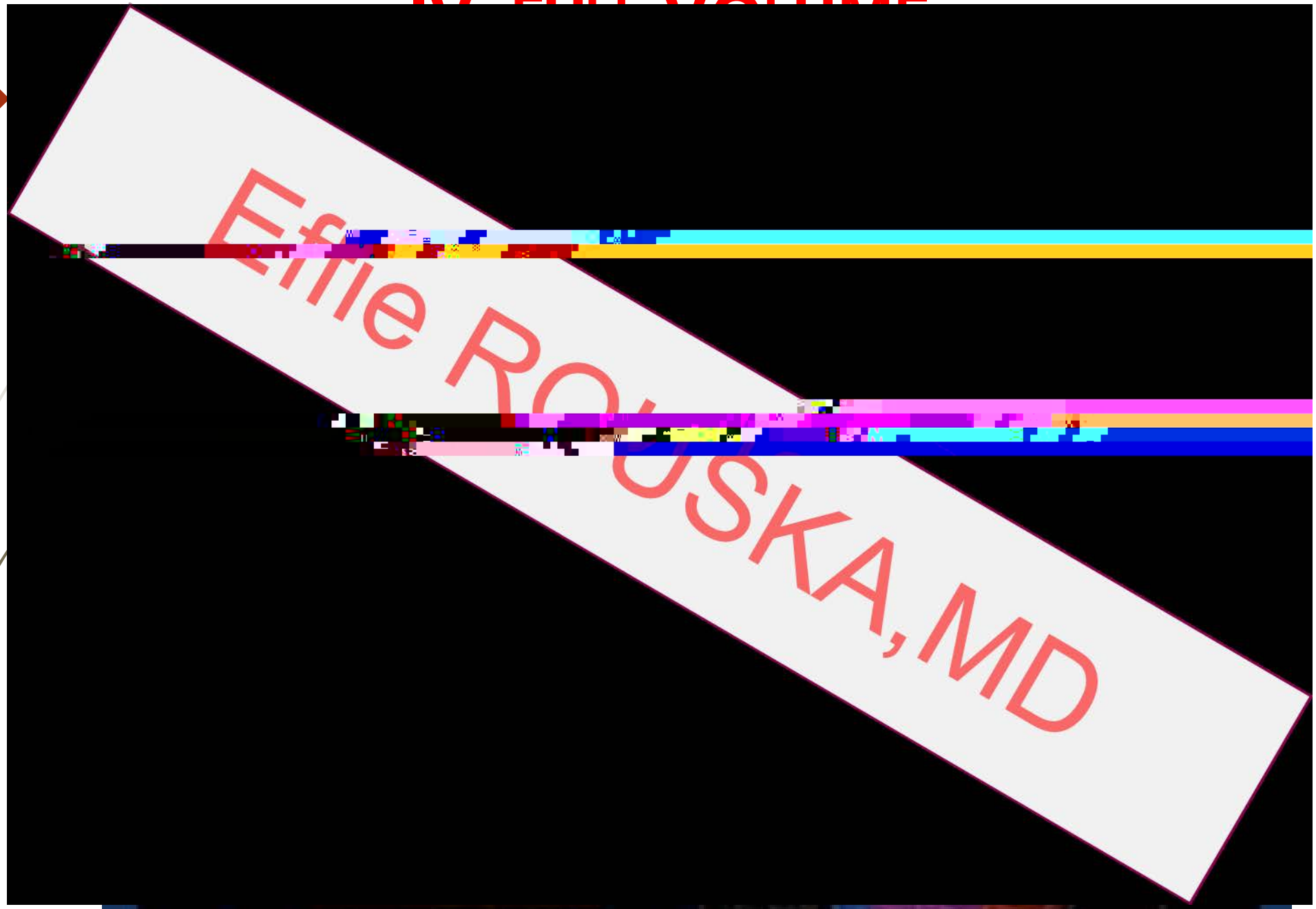


Effie ROUSKA,MD

Effie ROUSKA,MD

Val

Full

Mo

ssment

rocking

solution

Ad
Dis

Ful
Mo

Effie ROUSKA, MD


TIS0.6 MI 0.3
Effie ROUSKA,MD

Shadowing

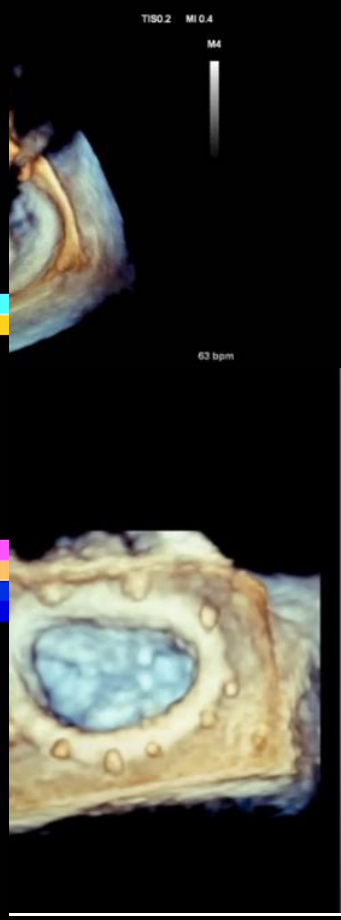

Effie ROUSKA,MD

ons



1. Dise

Assessm
and fun
patholo

ANATOMY



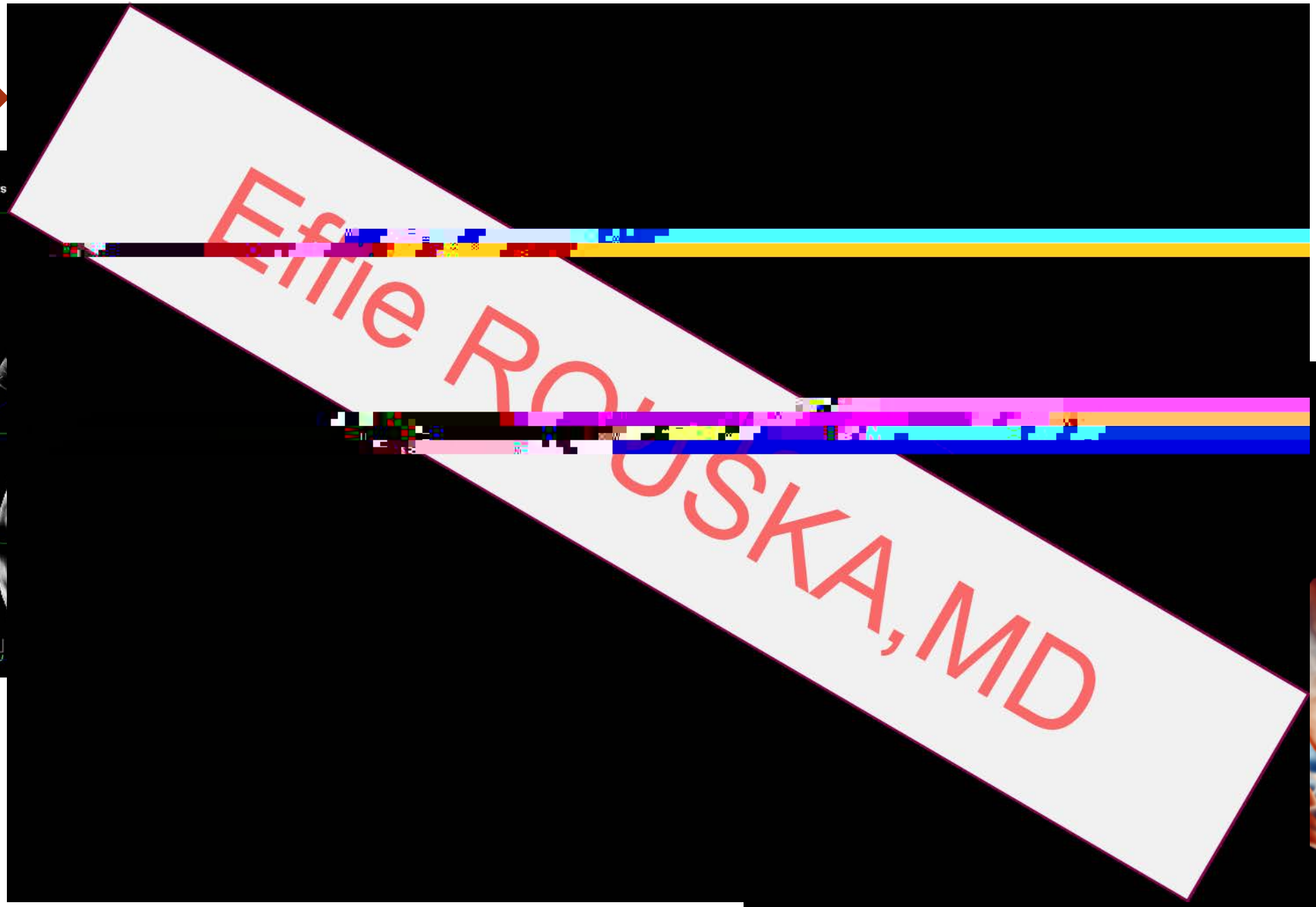

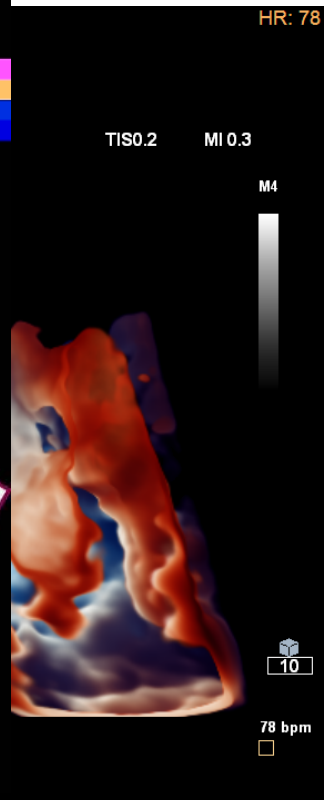

Effie ROUSKA, MD

Effie ROUSKA,MD

Effie R

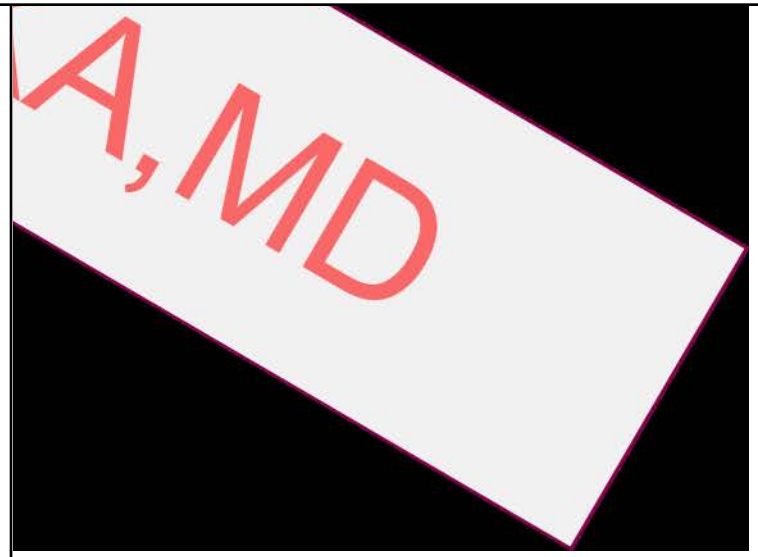
A,MD


0 1
Effie Rous

Effie ROUSKA,MD



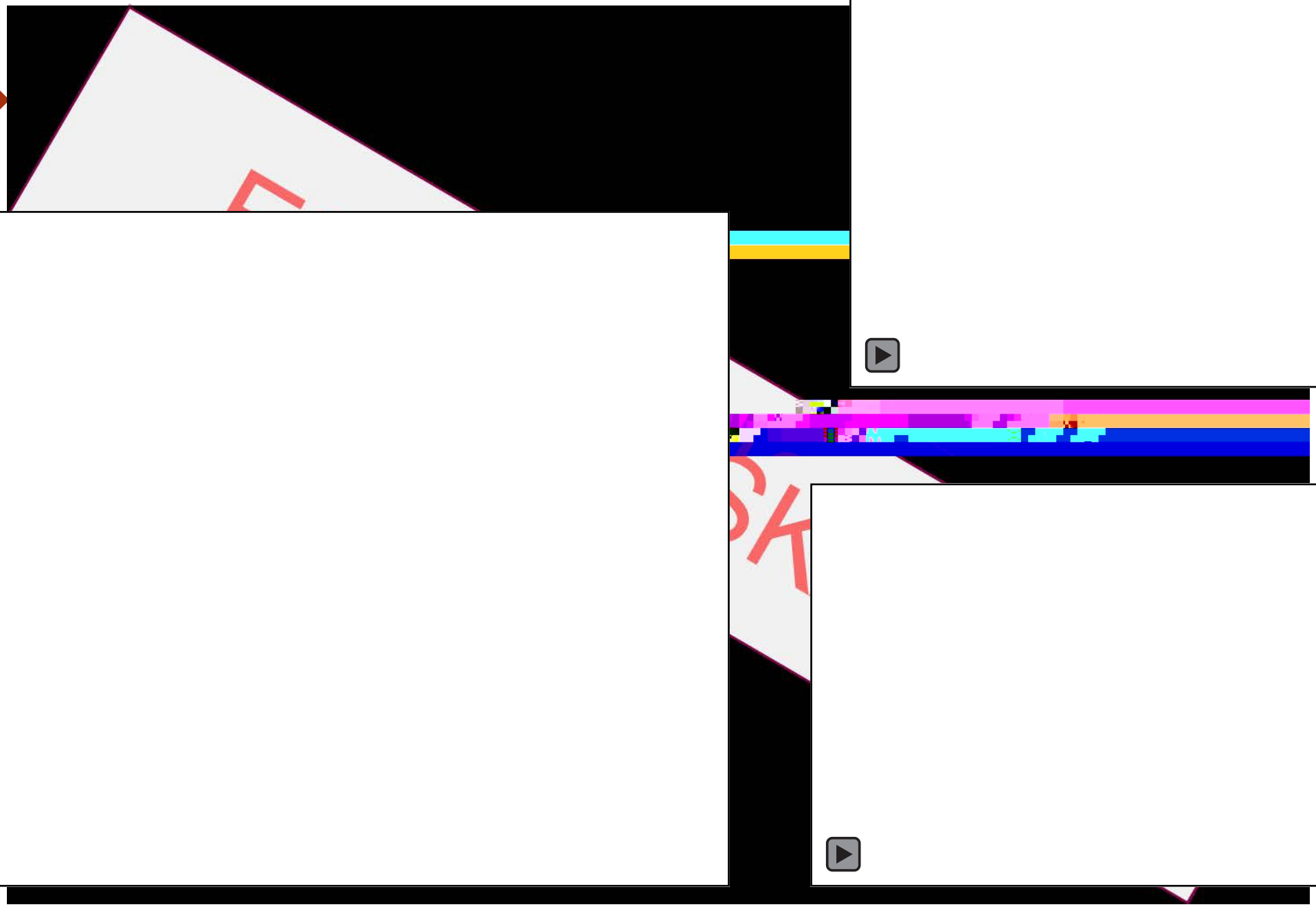

KA,MD

Effie ROUSKA,MD


Effie ROUSKA,MD



Effie ROUSKA, MD

[redacted]


Effie ROUSKA,MD
s:
77 bpm

Effie R

A,MD



Effie ROUSKA, MD

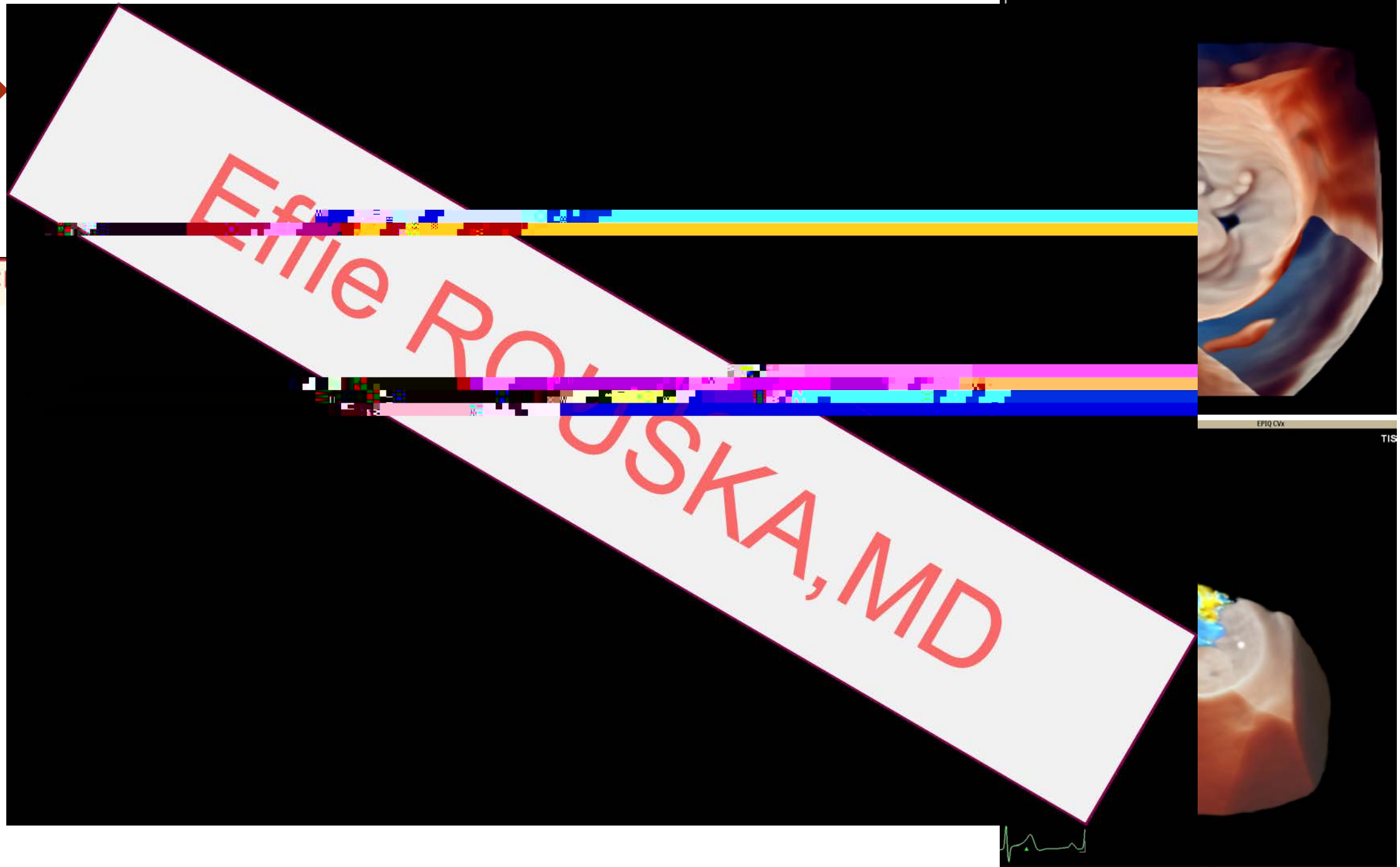

Effie ROUSKA, MD

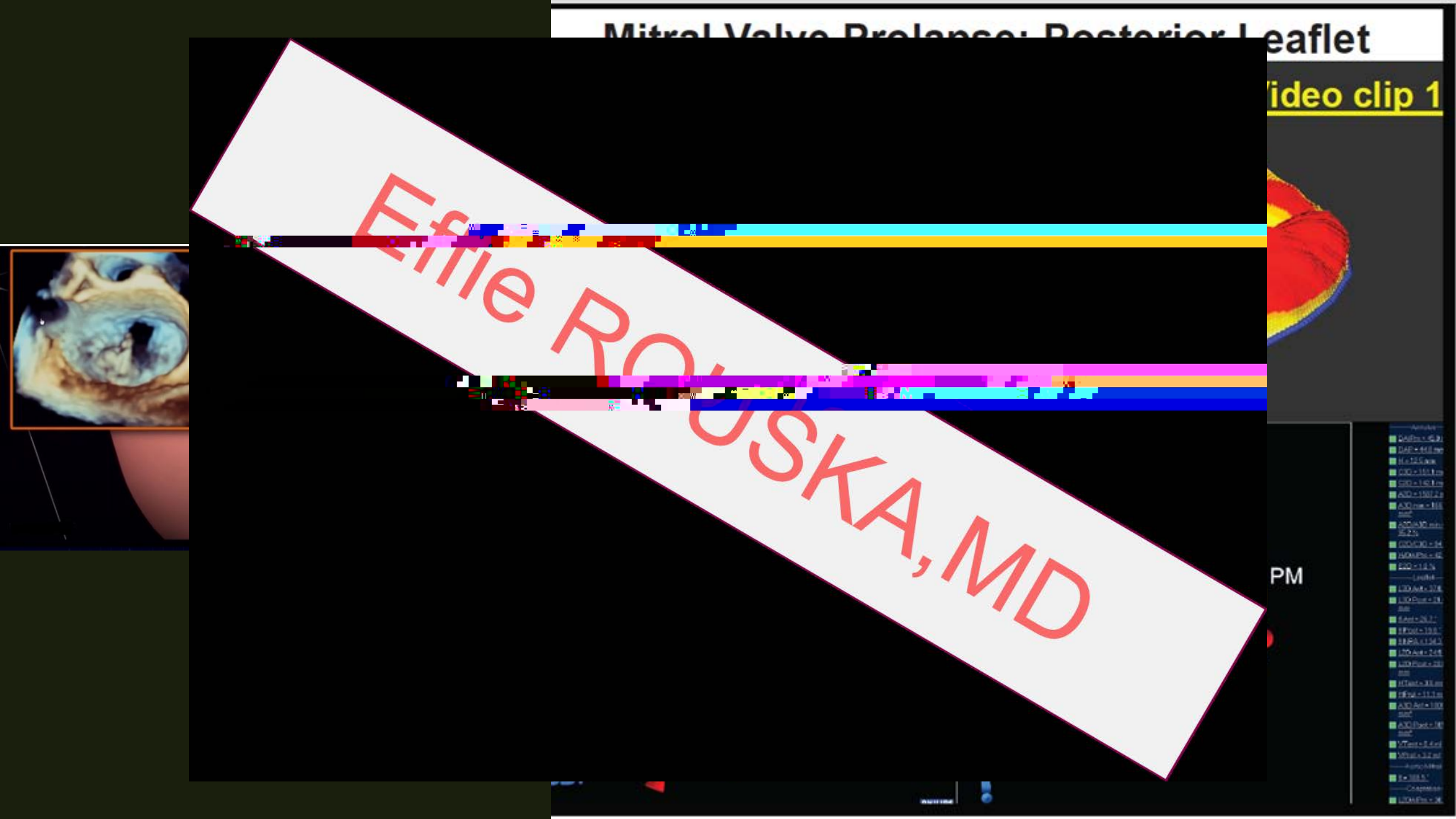

Effie ROUSKA, MD

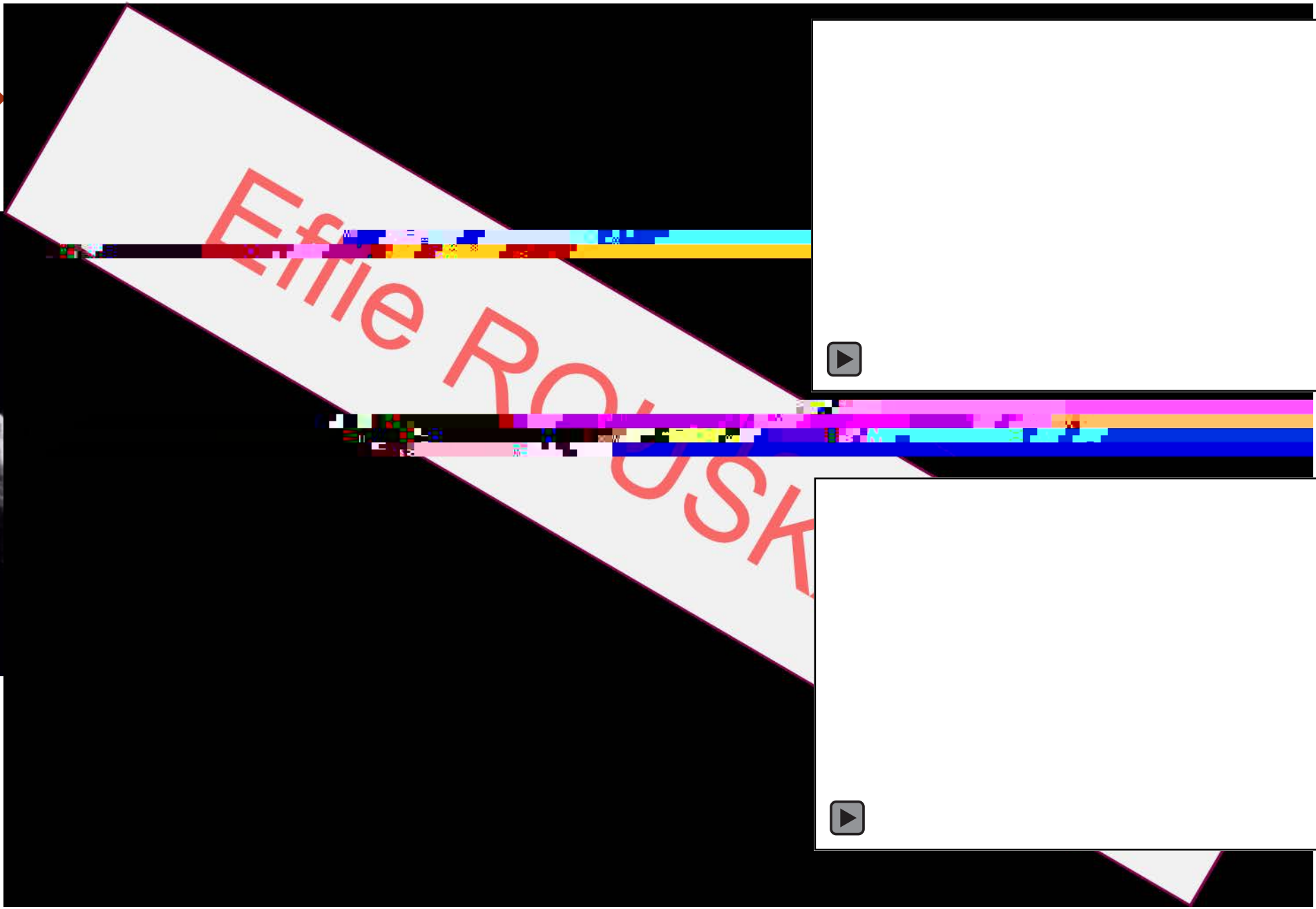
Effie ROUSK


Effie ROUSKA,MD

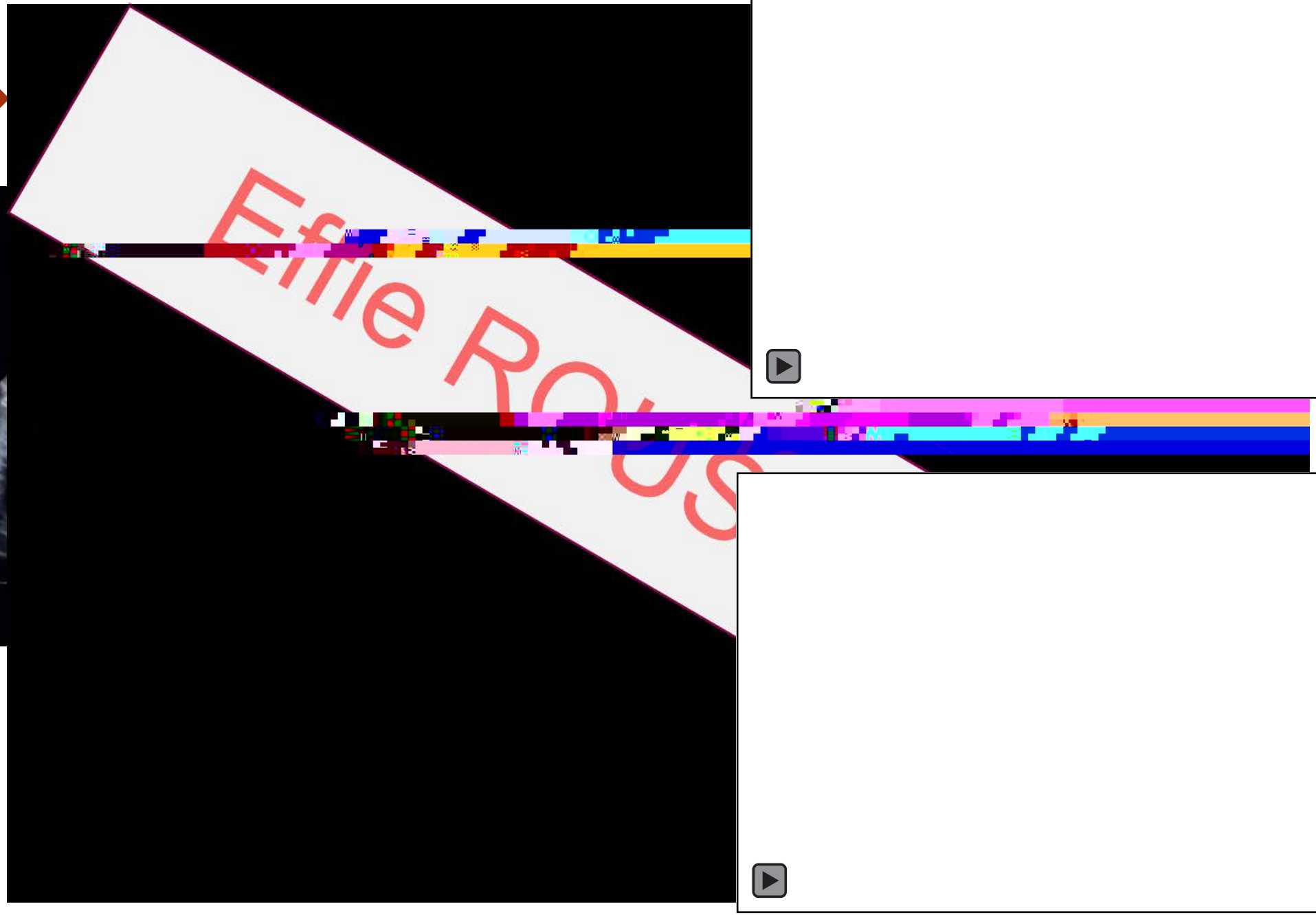
Effie Rous


Effie ROUSKA,MD


Effie ROUSKA,MD


Effie ROUSKA,MD



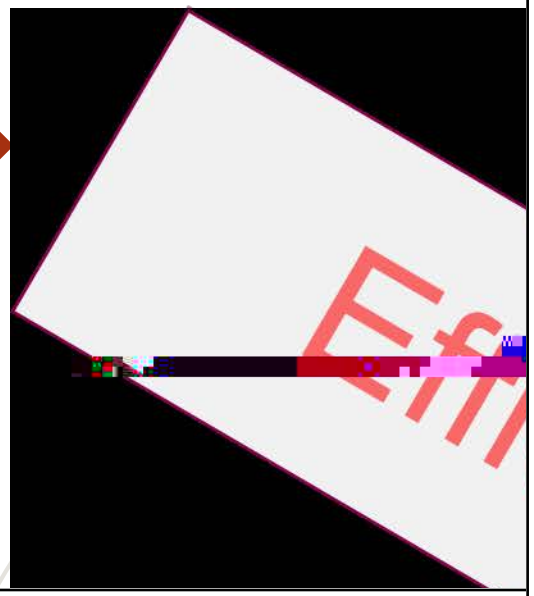
Effi

OKH



Effie ROUSKA, MD



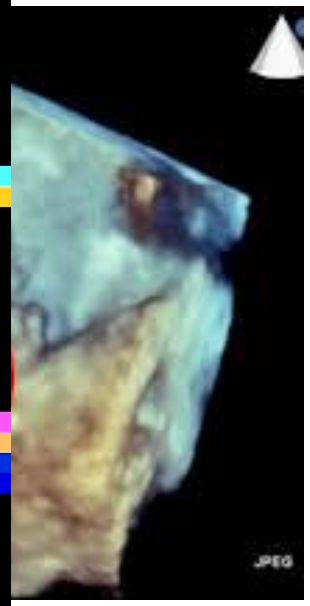



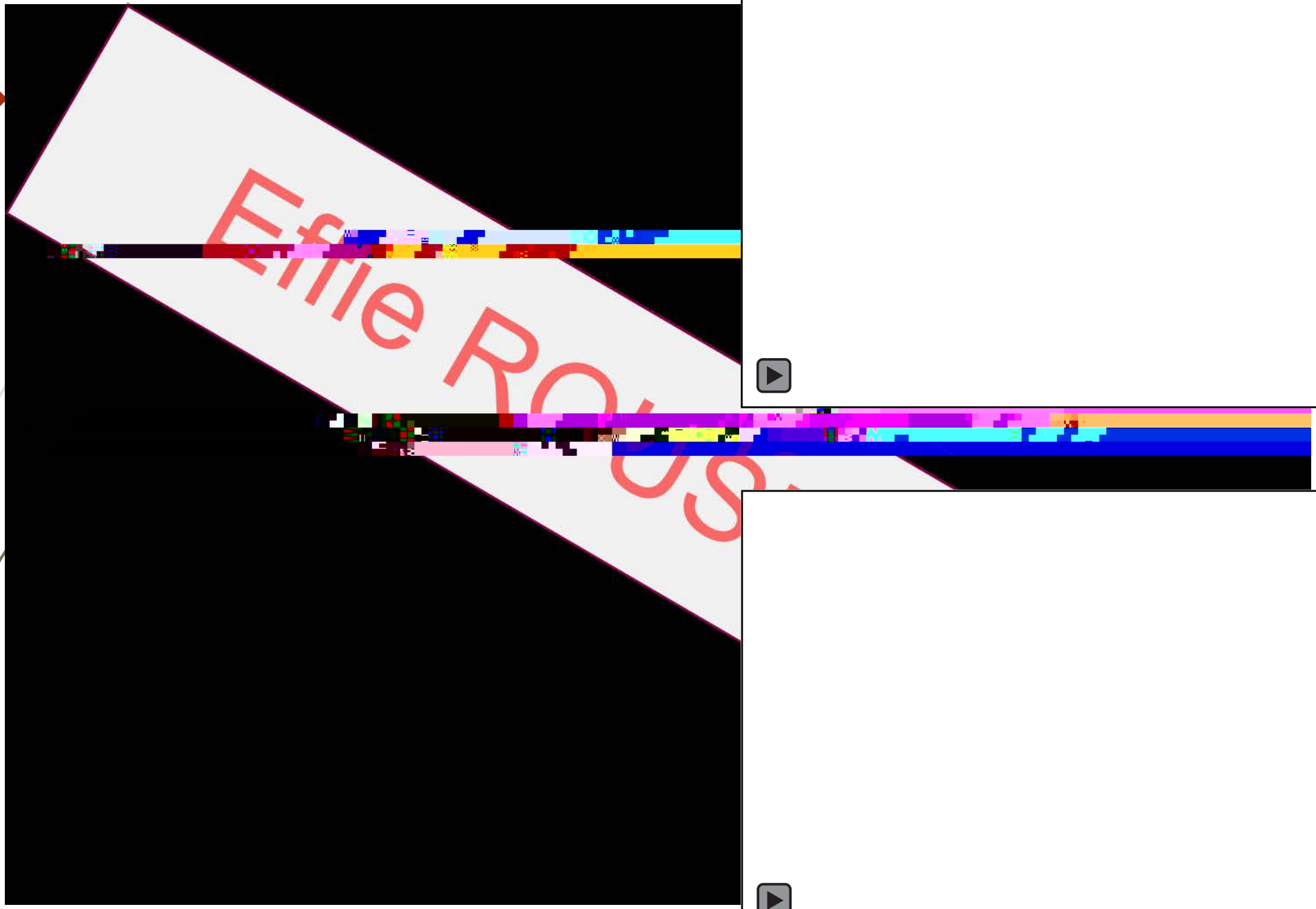
Effie Rous

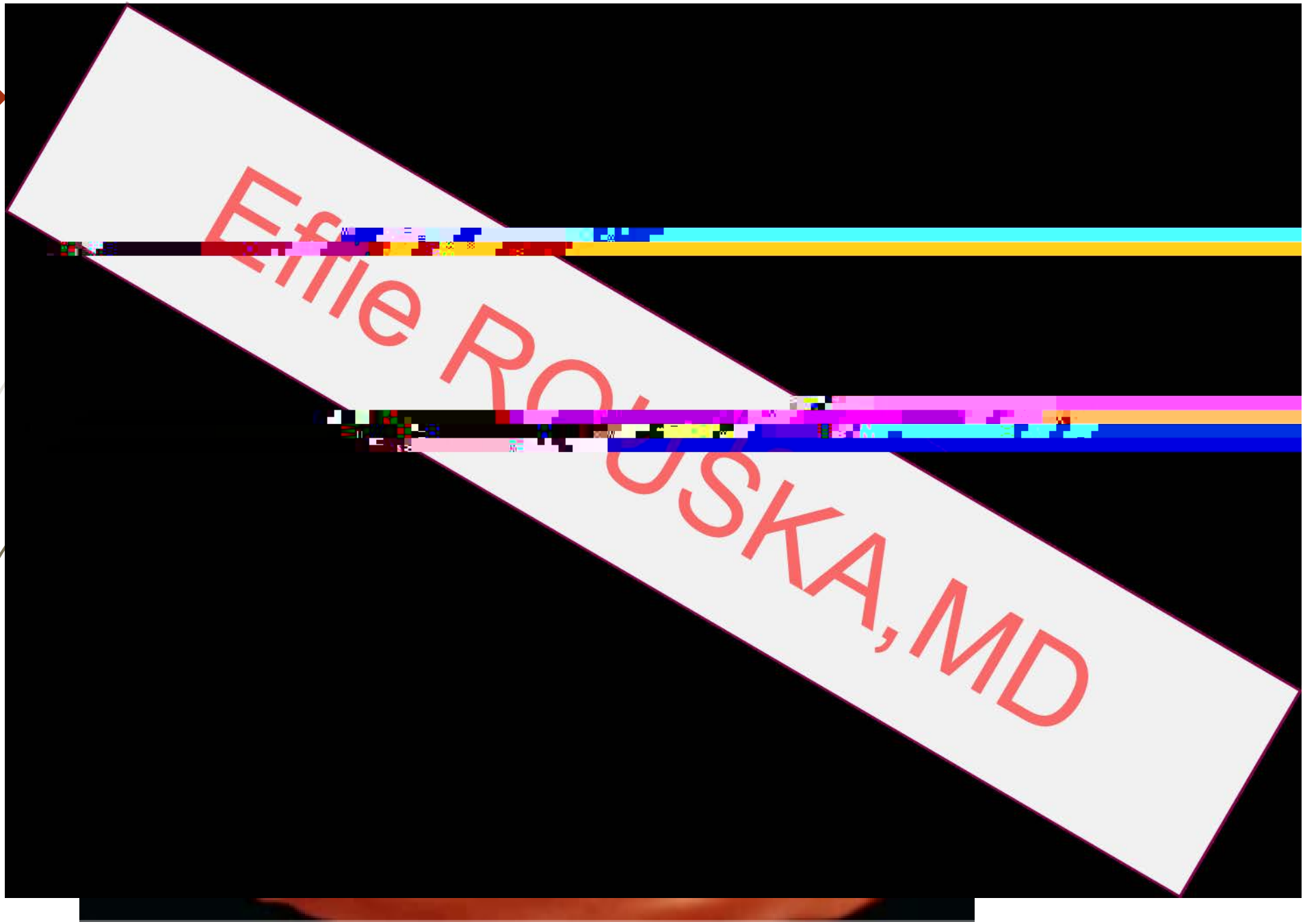
Effie ROUSKA, MD

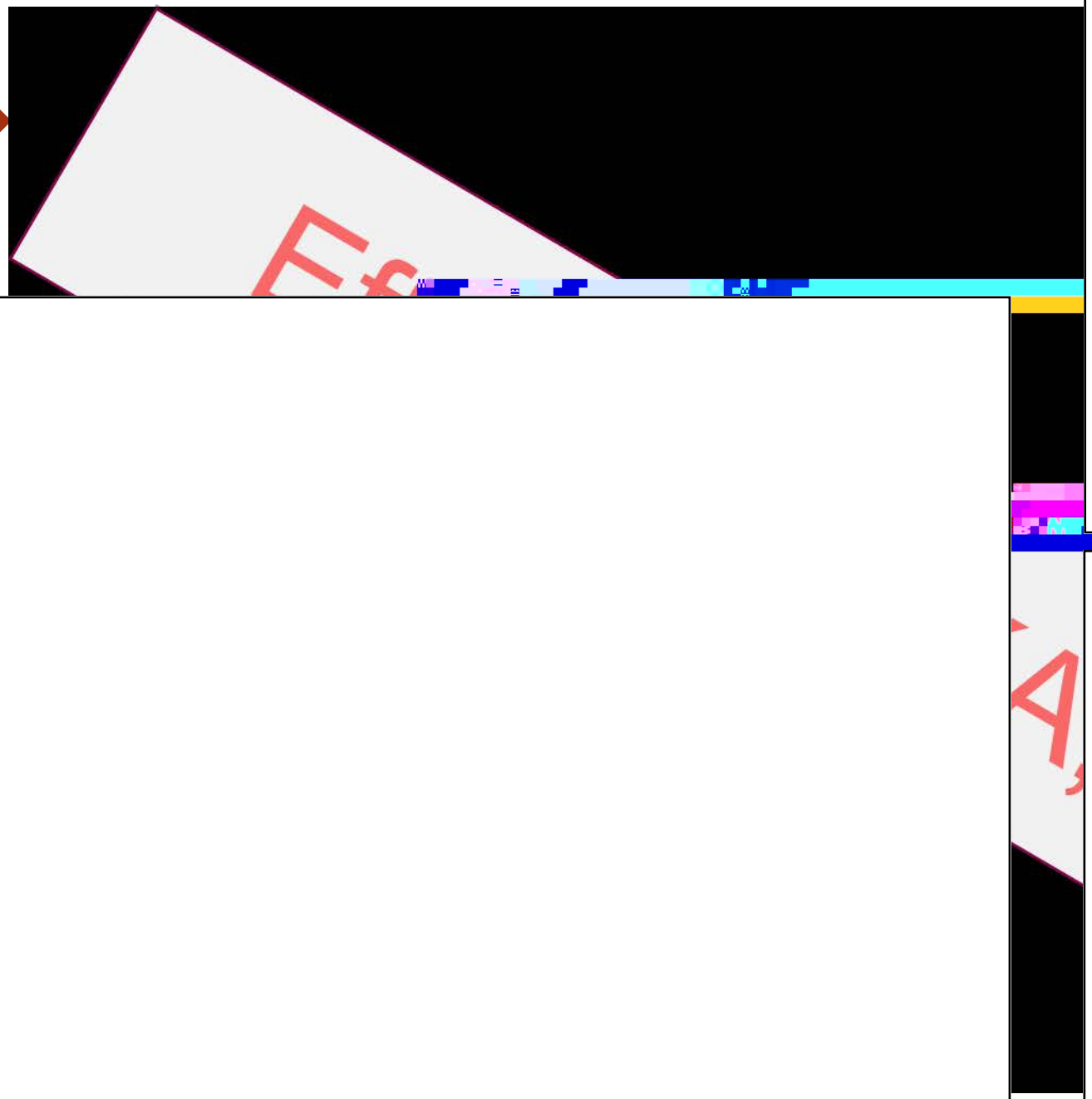

2. G
Inter

(per
and



Effie ROUSKA, MD

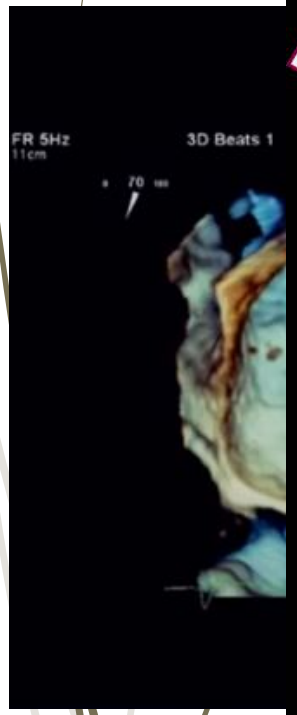

Effie ROUSKA, MD

3. As

(pe

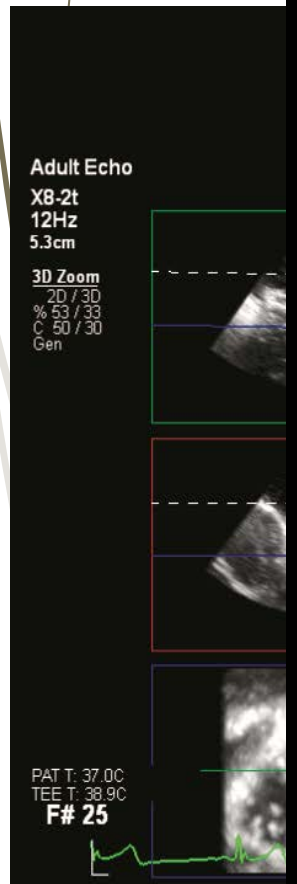
Adult Echo
X8-2t
12Hz
5.3cm
3D Zoom
2D / 3D
% 53 / 33
C 50 / 30
Gen
PAT T: 37.0C
TEE T: 38.9C
F# 25

Effie ROUSKA,MD

AO

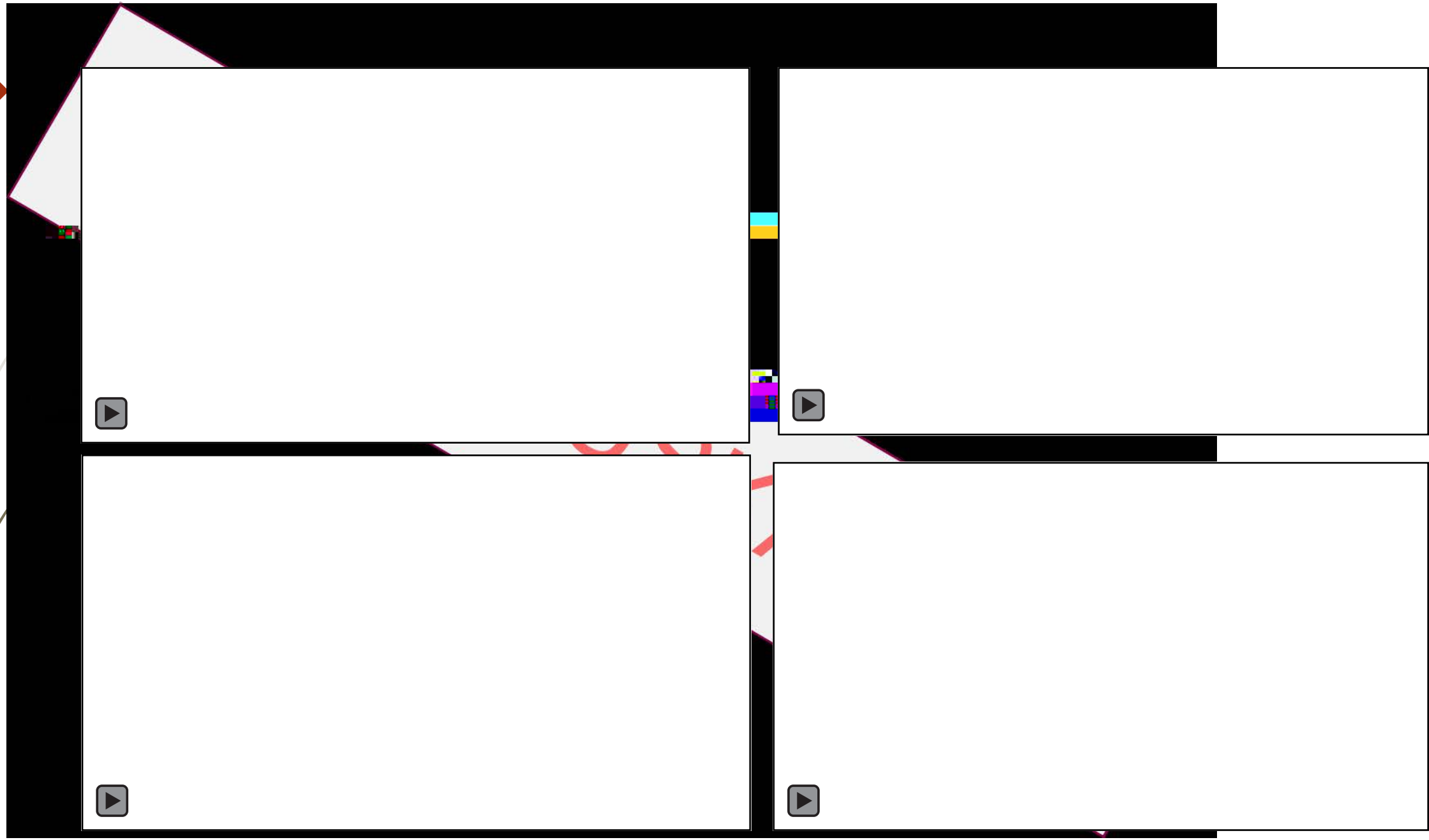

Effie Rous

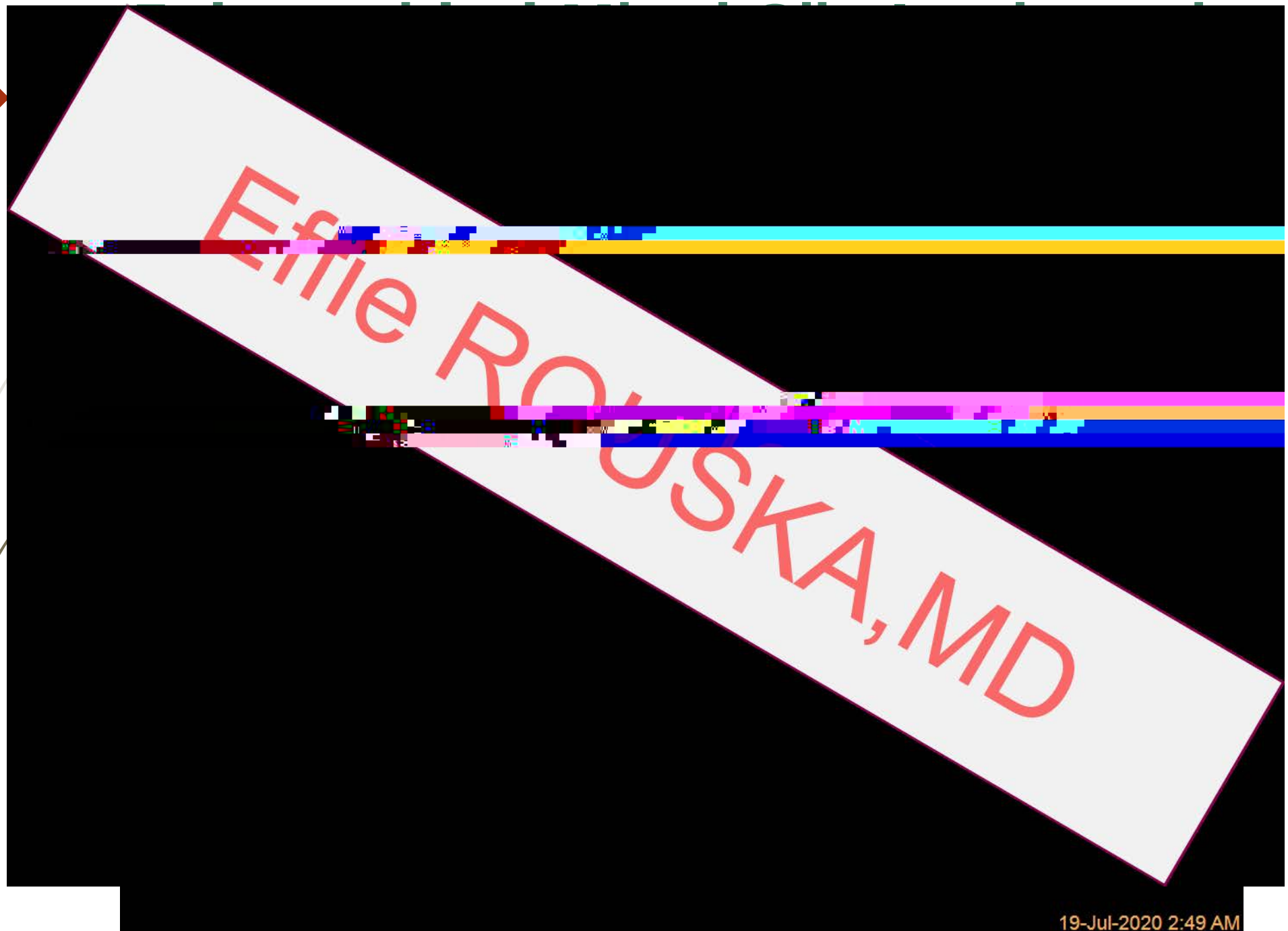
Effie ROUSKA,MD
19-Jul-2020 2:49 AM

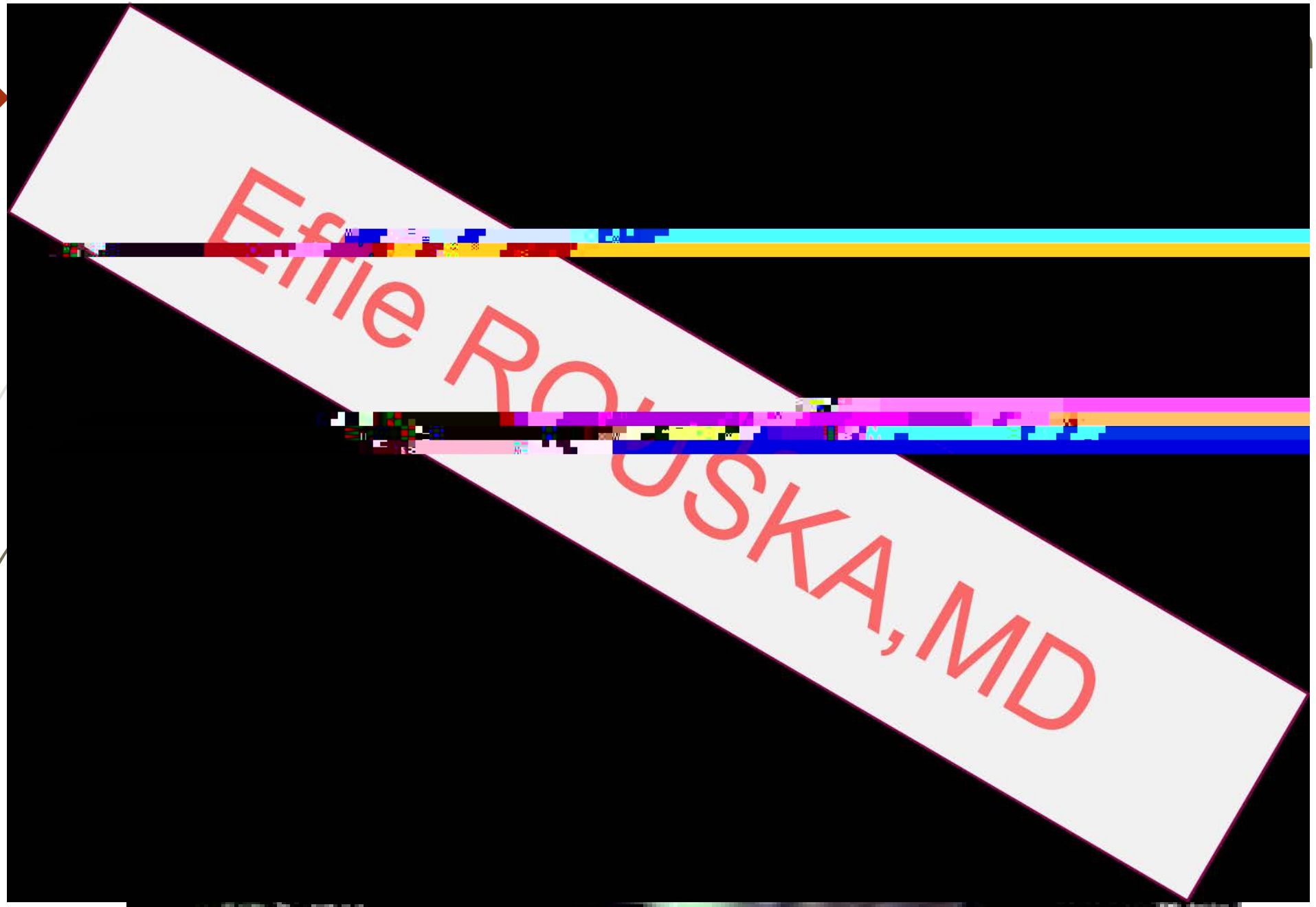
Effie ROUSKA,MD



Effie ROUSKA, MD

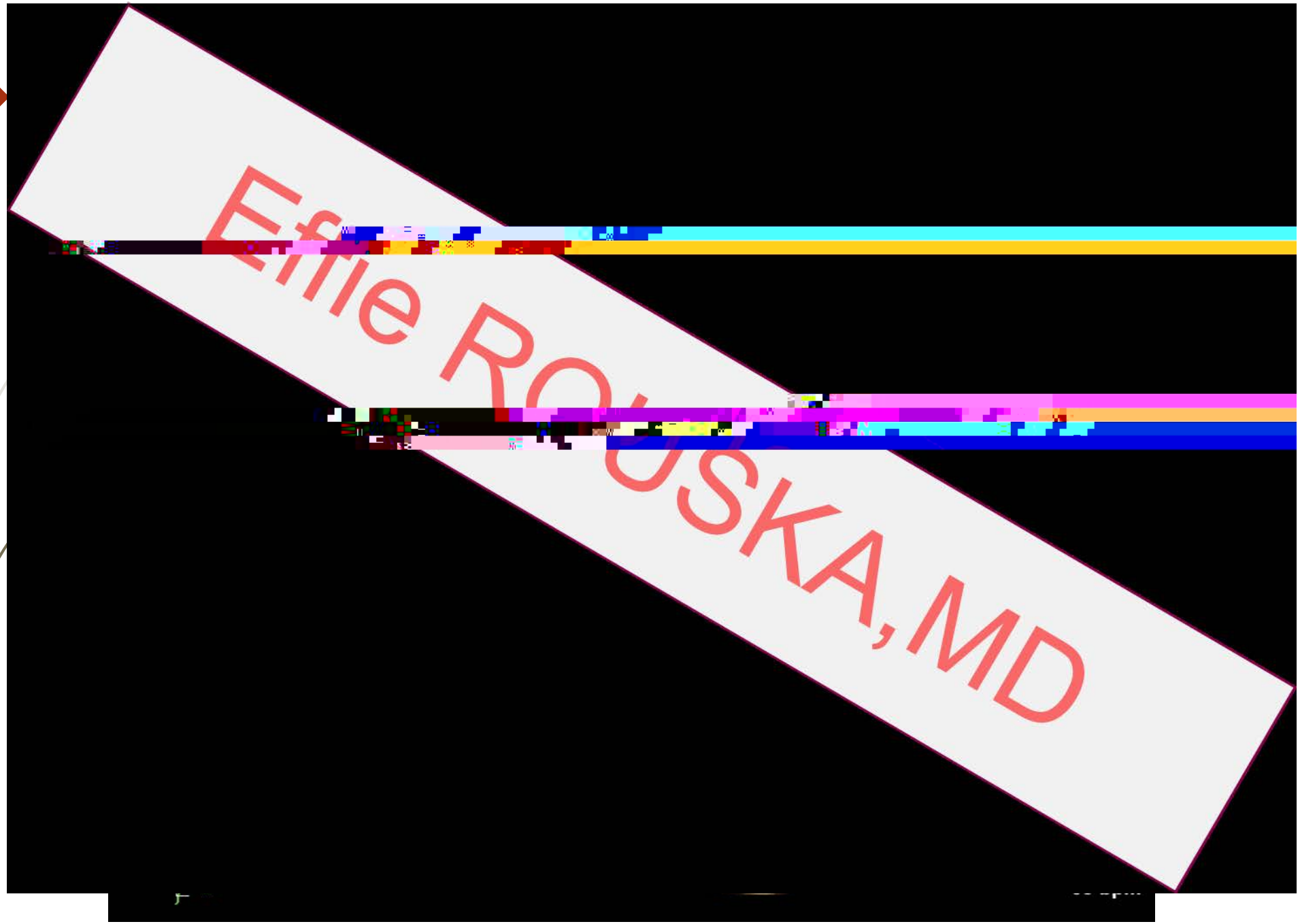
Effie ROUSKA,MD

0.5
Figure 2: Cor

Effie ROUSKA,MD
ERY and
Simplification

Pros

- Norm
- Dehi
- PVL
- Valv

	Current Status
relief mbogenic sk "clicking" vement in ry flow	Discontinued
EOA ogenicity nt flow olysis ise	Discontinued
blood flow ed EOA) blood flow ogenicity	Discontinued
urgitant ume y toward chanical ure ogenicity	Discontinued
regurgitant ume nce with sociated ivation and olysis ogenicity	Most popular mechanical design accounts for ~80% of implanted valves

Effie ROUSKA,MD

on

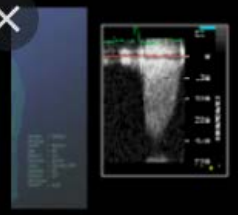

SE/EACV
of Norm

Philippe Pi
Canada

Effie ROUSKA,MD

	Bioprosthetic MVR
namics alve	Central orifice, laminar flow, blunt flow profile
limit n TTE. otion EE	Stented valve, flow directed toward septum Trileaflet porcine or pericardial tissue similar to that of a native aortic valve
y short T½ R due to e	Antegrade velocity <1.9 m/s with short T½ No to trace central MR
m	Variable durability, longer in older patients Does not require anticoagulation (but may be needed for AF)
	Leaflet degeneration Stenosis Regurgitation Pannus Paravalvular A Endocarditis
	Baseline post-op Changing signs or symptoms Annual starting 5 years after implantation

C
PAT T: 37.0C
TEE T: 36.7C

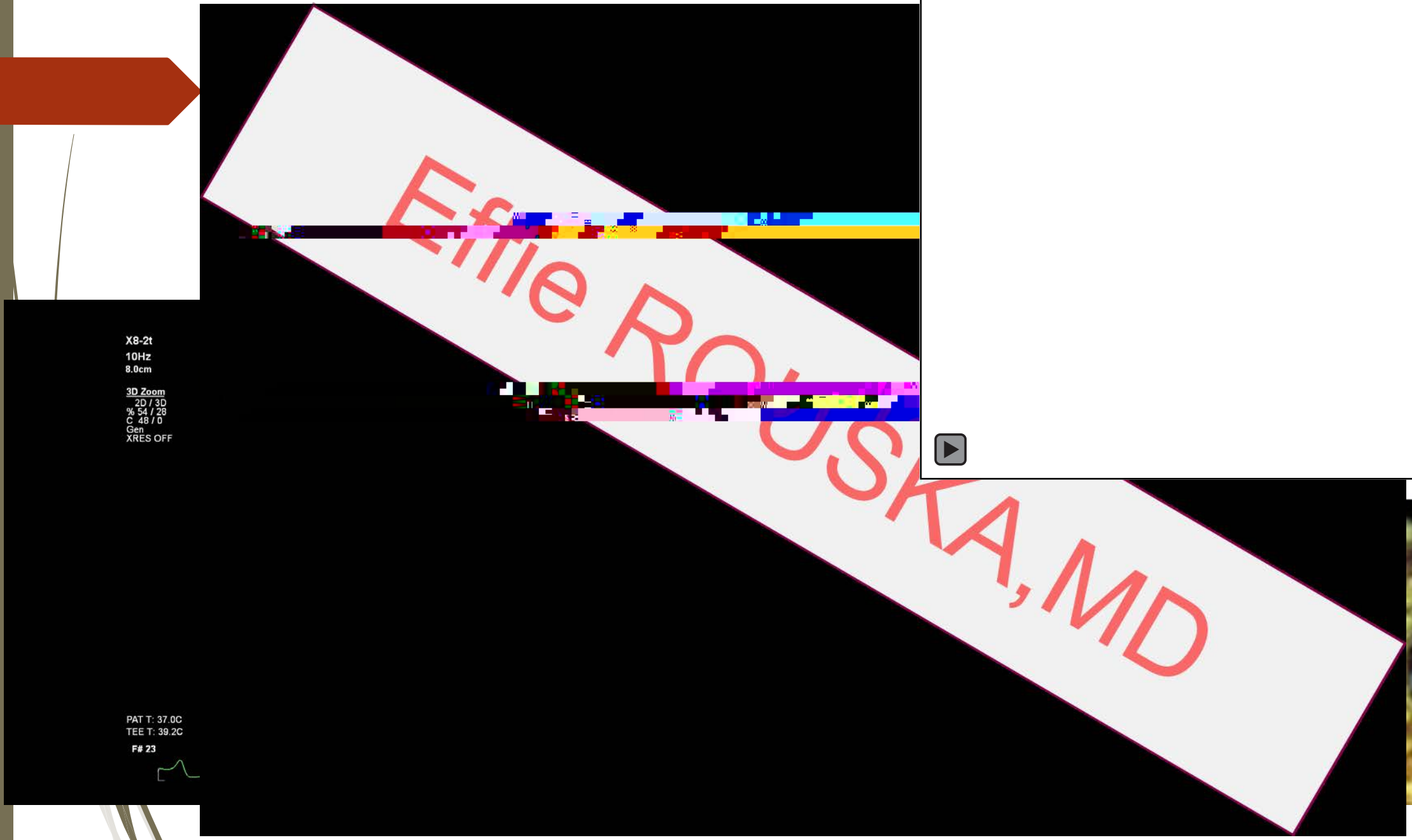
X8-2t
10Hz
8.0cm
3D Zoom
2D / 3D
% 54 / 28
C 48 / 0
Gen
XRES OFF
PAT T: 37.0C
TEE T: 39.2C
F# 23
Effie ROUSKA,MD

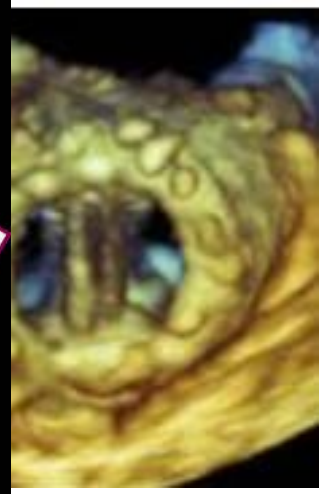

idos 3D 1
Effie ROUSKA,MD


Effie

USP

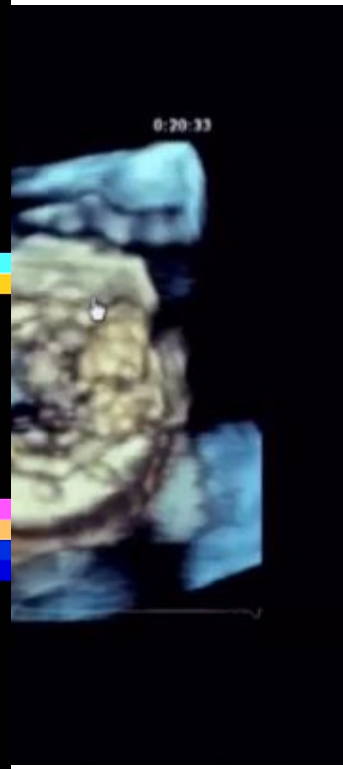

Effie ROUSKA, MD

4. Ass

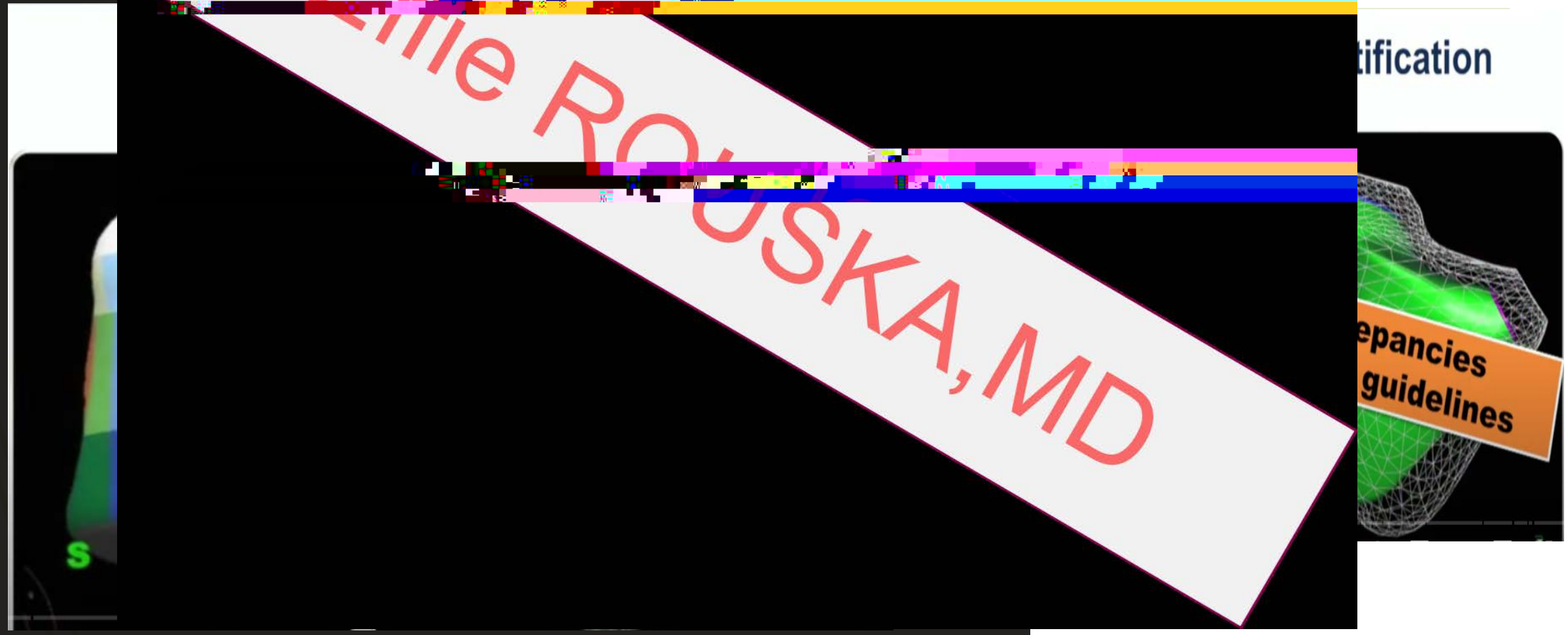

Effie ROUSKA,MD

Fully Automated Cardiac Chamber
3D LV End-Diastolic Volume
3D LV End-Systolic Volume
LV Ejection Fraction
3D LA Volume at LV End-Systole
2D
M-mode
WMA scoring
Visual EF
Routine clinical use
Limited clinical use
Mainly research
No longer recommended
Effie ROUSKA,MD

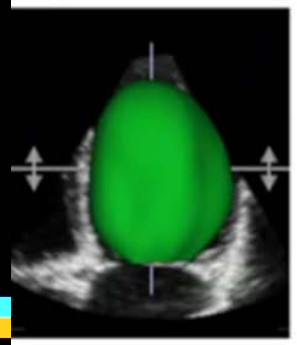

vantages
emporal
ution
data on
als

f normal:
n
men
n
28 ml/m² for women

Effie ROUSKA,MD

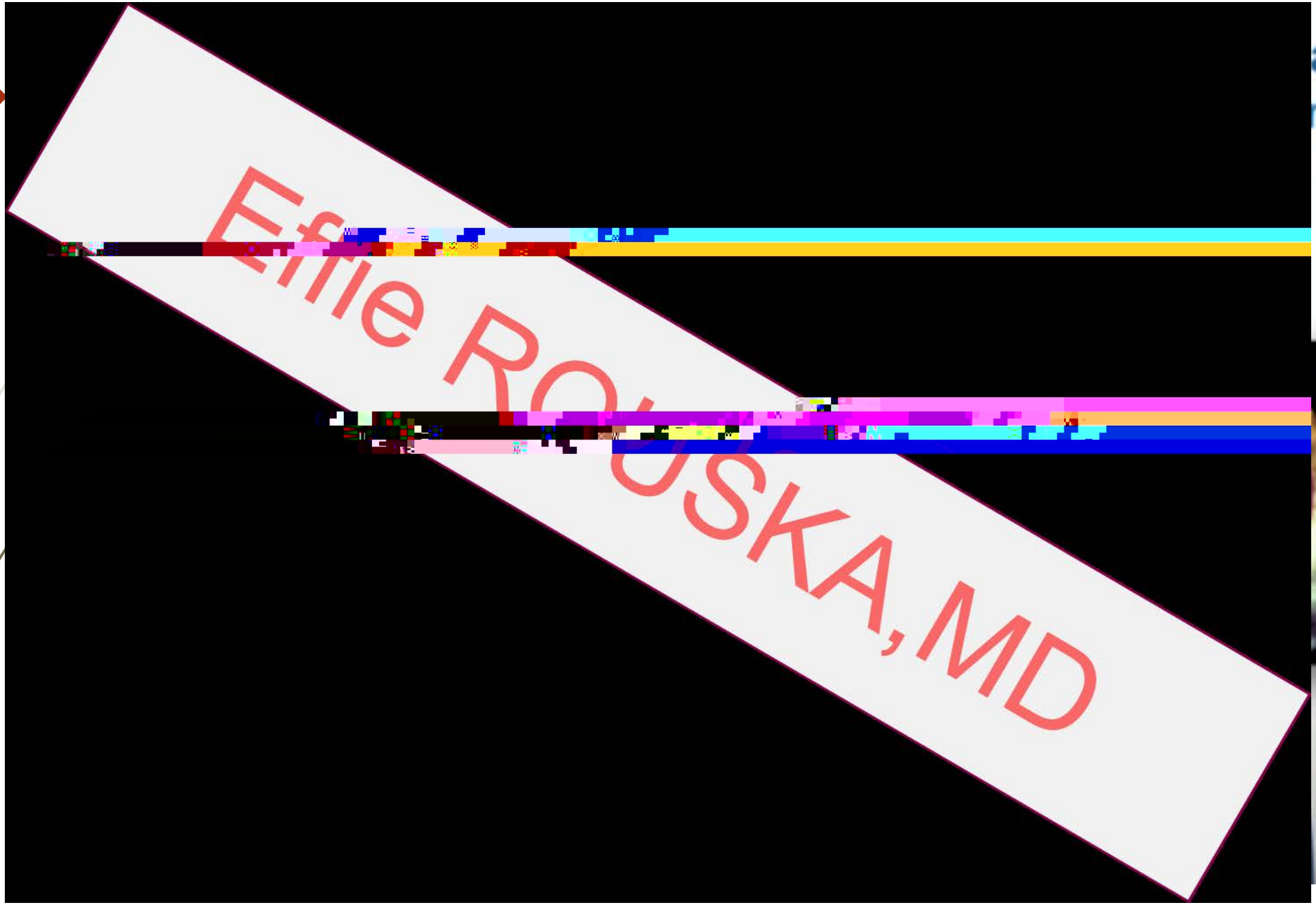
Effie ROUSKA,MD

Dynar
Heart
for LV
& func

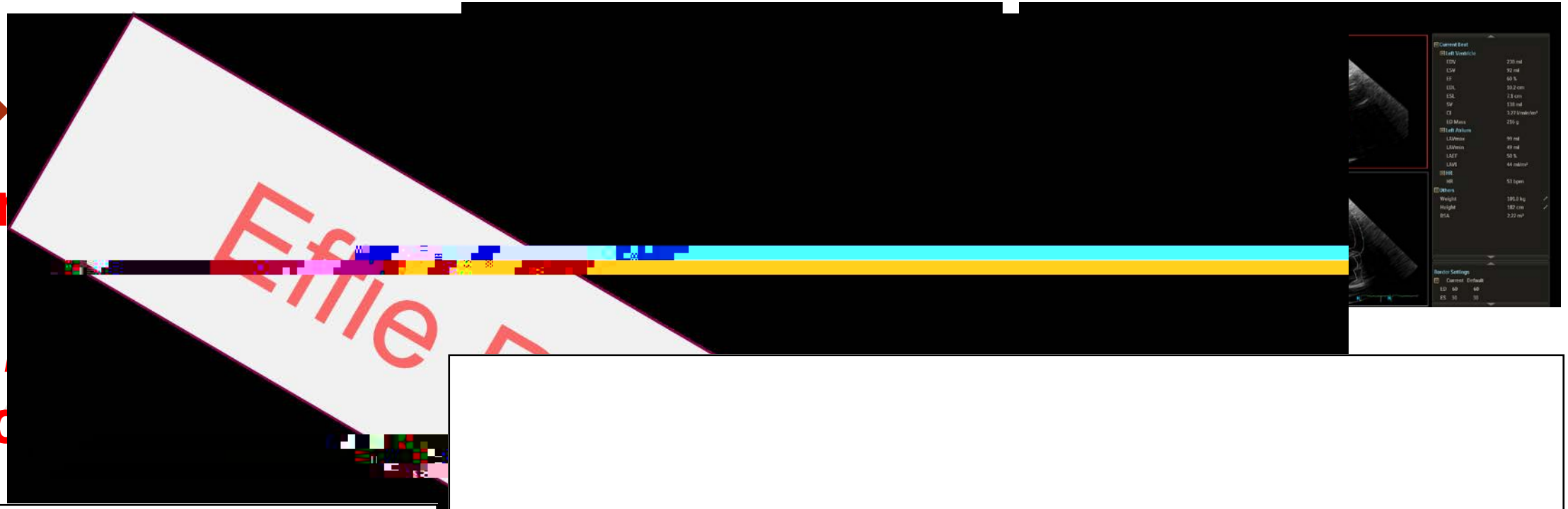

[redacted]

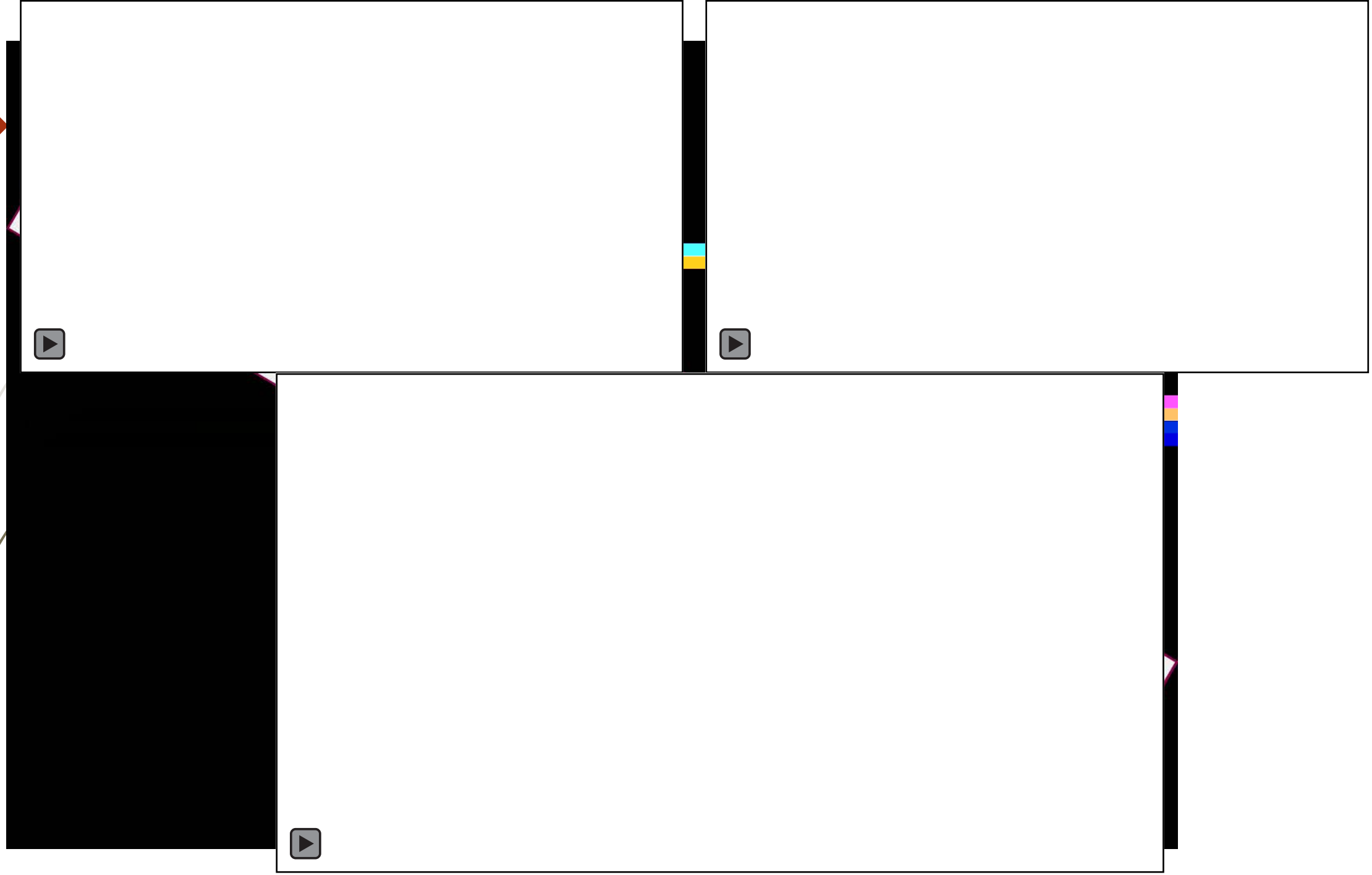

e to minimal
me

c
ny index
culation)

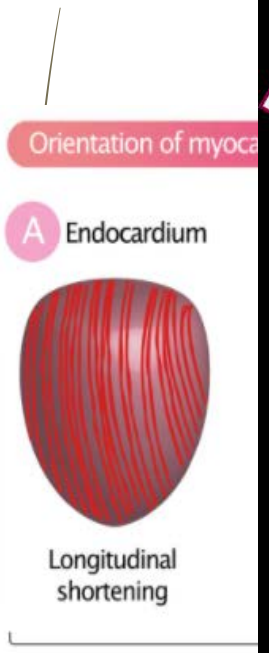

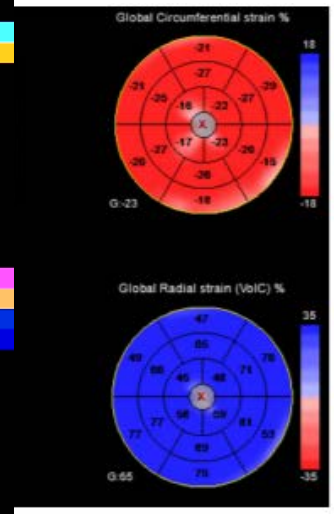

healthy subject.

ain (negative—
lor) are

ve map, the
meter (G,

Effie ROUSKA,MD

G

Lon
rob
car

&

cor



Effie Rous

curves

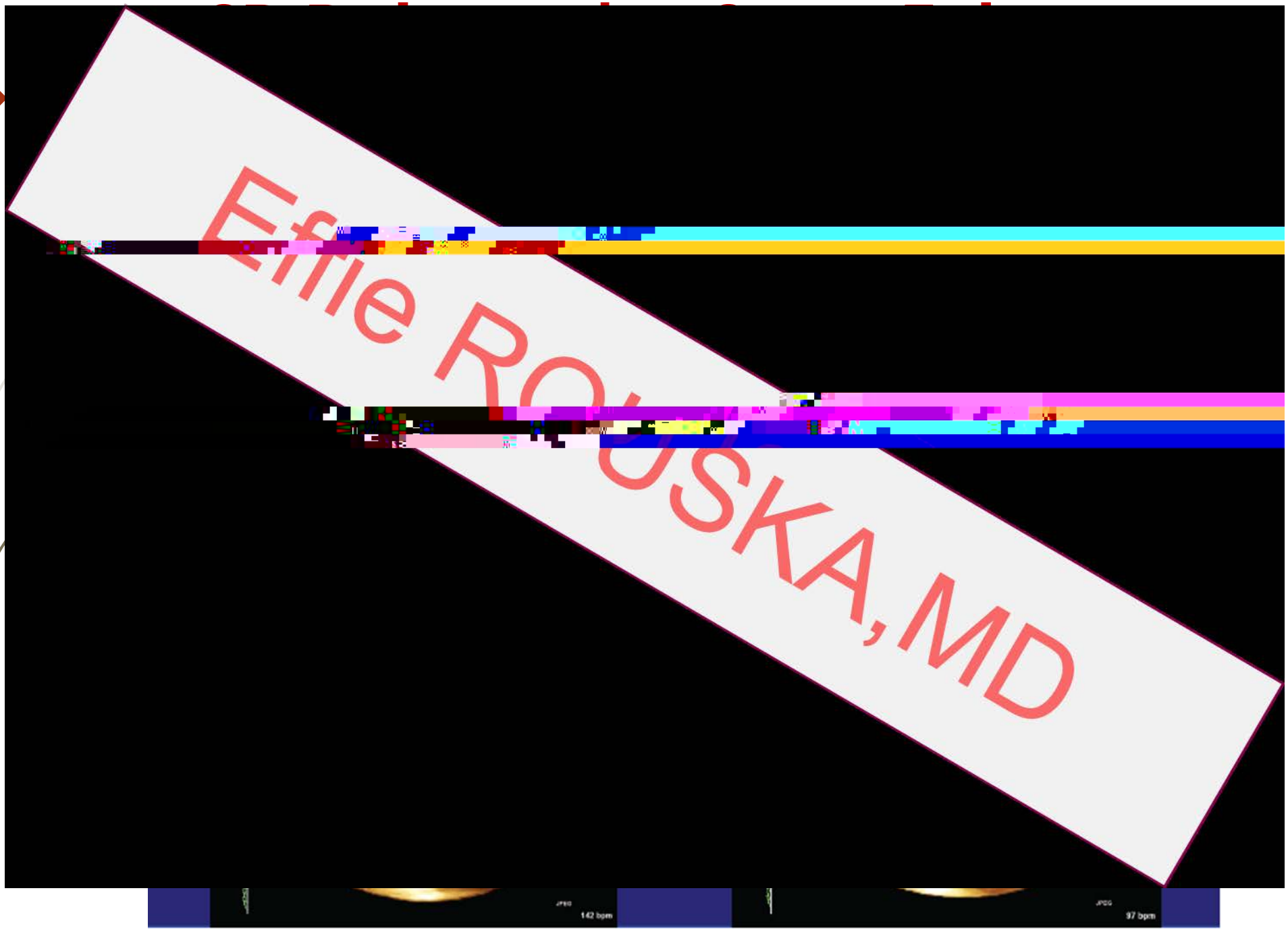

Effie ROUSKA,MD

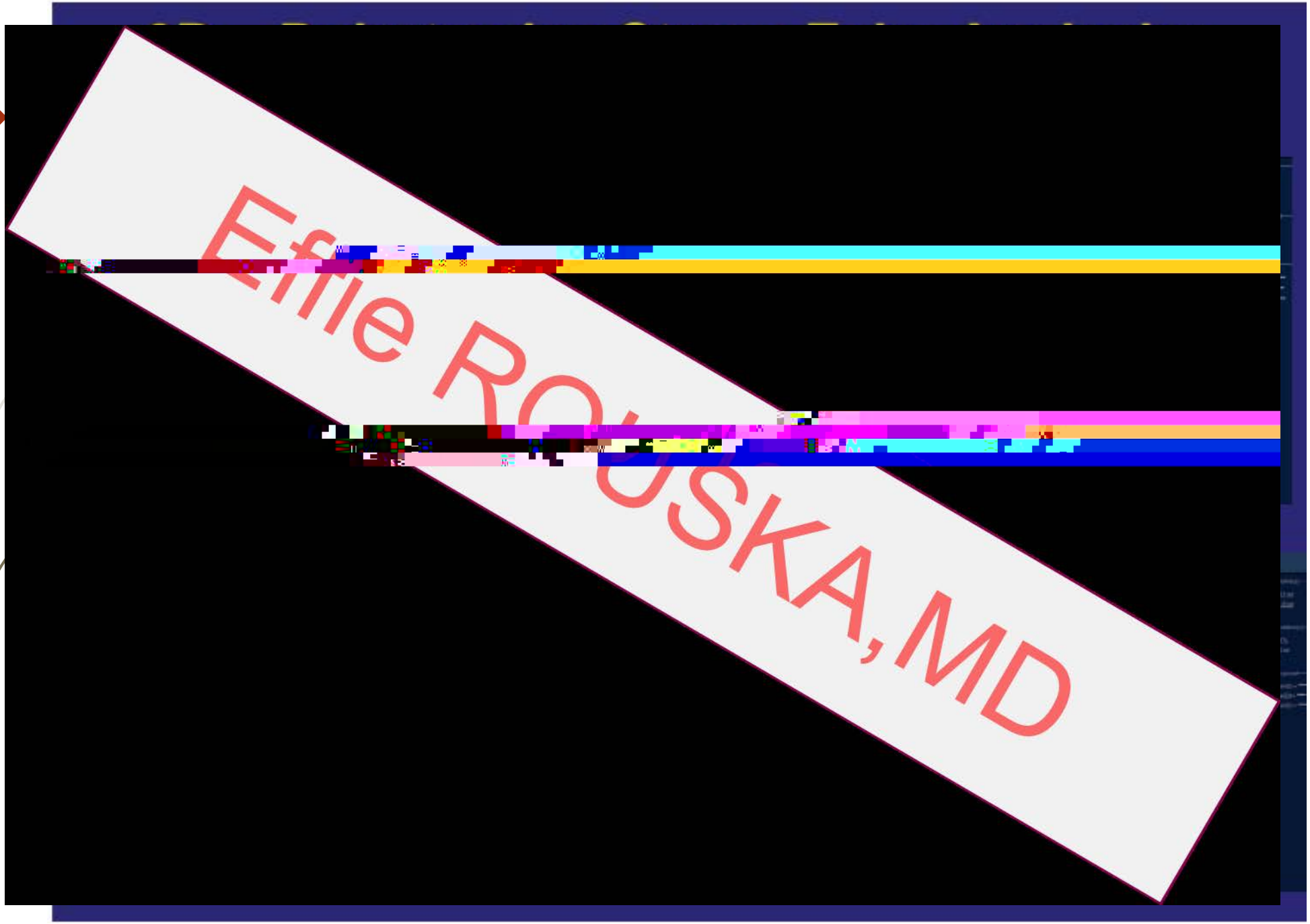
Effie ROUSKA,MD

Cardiac Resynchronization Therapy

Using
the segmental to minimal systolic volume (TMSV) and systolic dyssynchrony index (SDI)

- For the analysis of LV dyssynchrony, **individual LV segmental volumes are plotted versus time** throughout the cardiac cycle.
- These plots allow measurement of temporal differences in segmental TMSV and **automatic calculation of SDI** from the standard deviation of regional TMSV
- The **device is programmed** for the A-V and V-V intervals that produce the lowest systolic SDI.
- Using a 3D echo protocol, **CRT reduces the SDI**, resulting in improved ejection fraction in about 80% of cases
- This cardiac resynchronization leads to **symptomatic improvement** that usually lasts for a minimum of 6 months

Effie ROUSKA, MD

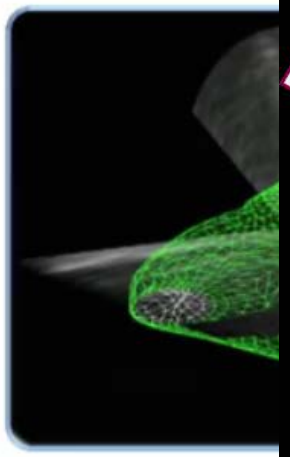

RV Volu
Echocar

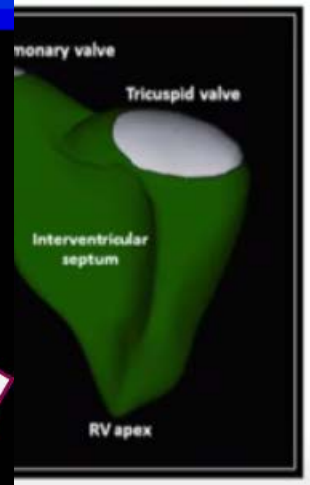

V EF % 58±6.5

RV ESV/BSA, Men	27±6.5	10-44	
RV ESV/BSA, Women	22±7	8-36	<45

Effie ROUSKA, MD


Effie R

Effie ROUSKA,MD

Effie ROUSKA,MD

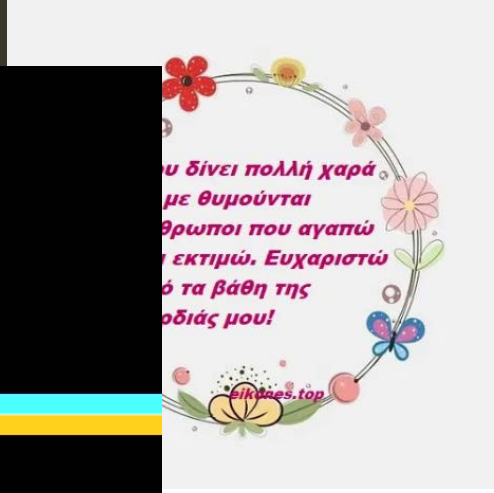

Effie ROUSKA,MD

Live Imaging

Live imaging can be performed in the following modes:

- **real-time narrow sector,**
- **focused wide sector,**
- and **single-beat full-volume mode**

Each of these modes can be acquired **with or without CFD** information.

Effie Roussakis

R-Wave Gated Multibeat Acquisition

There are three R-wave gated 3D image acquisition modes:

- **R-wave gated multiple-beat acquisitions without CFD**,
- **R-wave gated multiple-beat acquisitions with CFD**,
- and **wide-angle "zoom" multibeat acquisition**.

R-wave gated acquisition is based on piecemeal examination of a structure (eg, mitral valve with multiple frustums/volumes that are generated sequentially in synchrony or gated to the R wave of the ECG).

Because each frustum has a high line density and temporal resolution, the final reconstructed image is predictably of a very high quality

Effie Roussakis

Effie ROUSKA, MD



Effie ROUSKA,MD

Effie ROUSKA, MD

Effie ROUSKA,MD

ECHO
FUSION

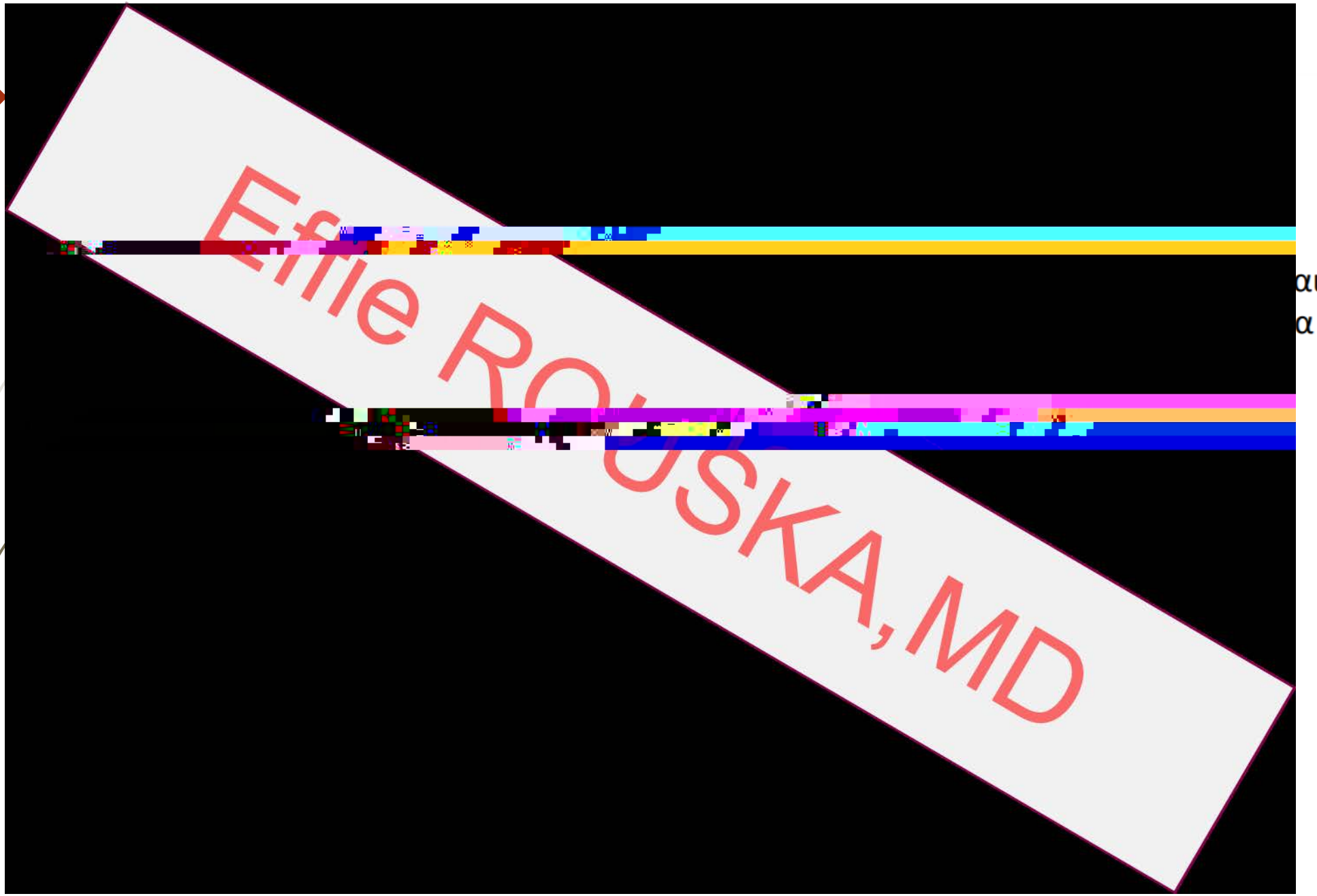

αι
α

Effie ROUSKA,MD

Effie ROUSKA,MD