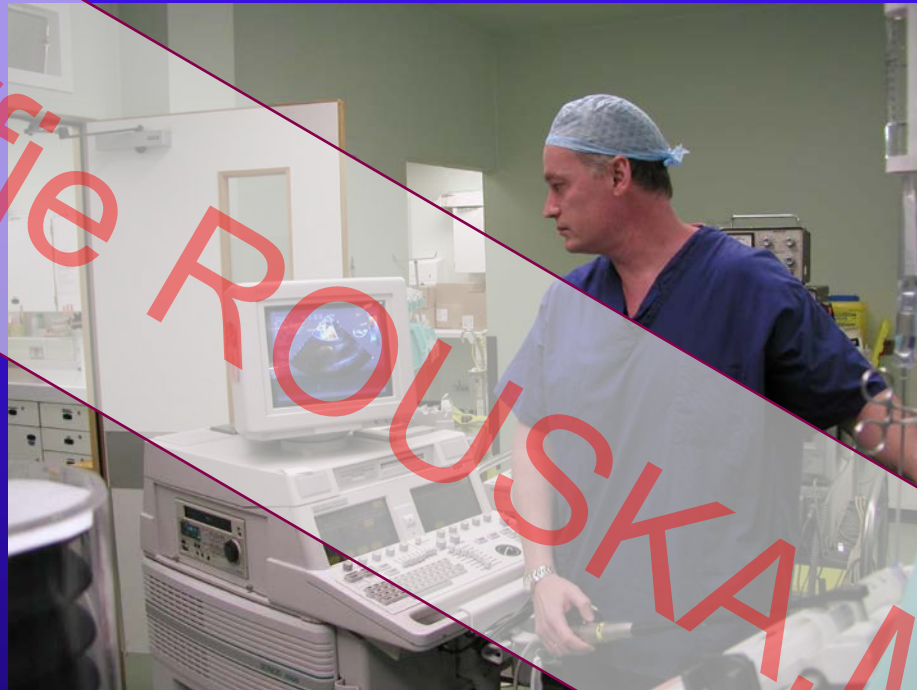

# Comprehensive intraoperative TOE examination



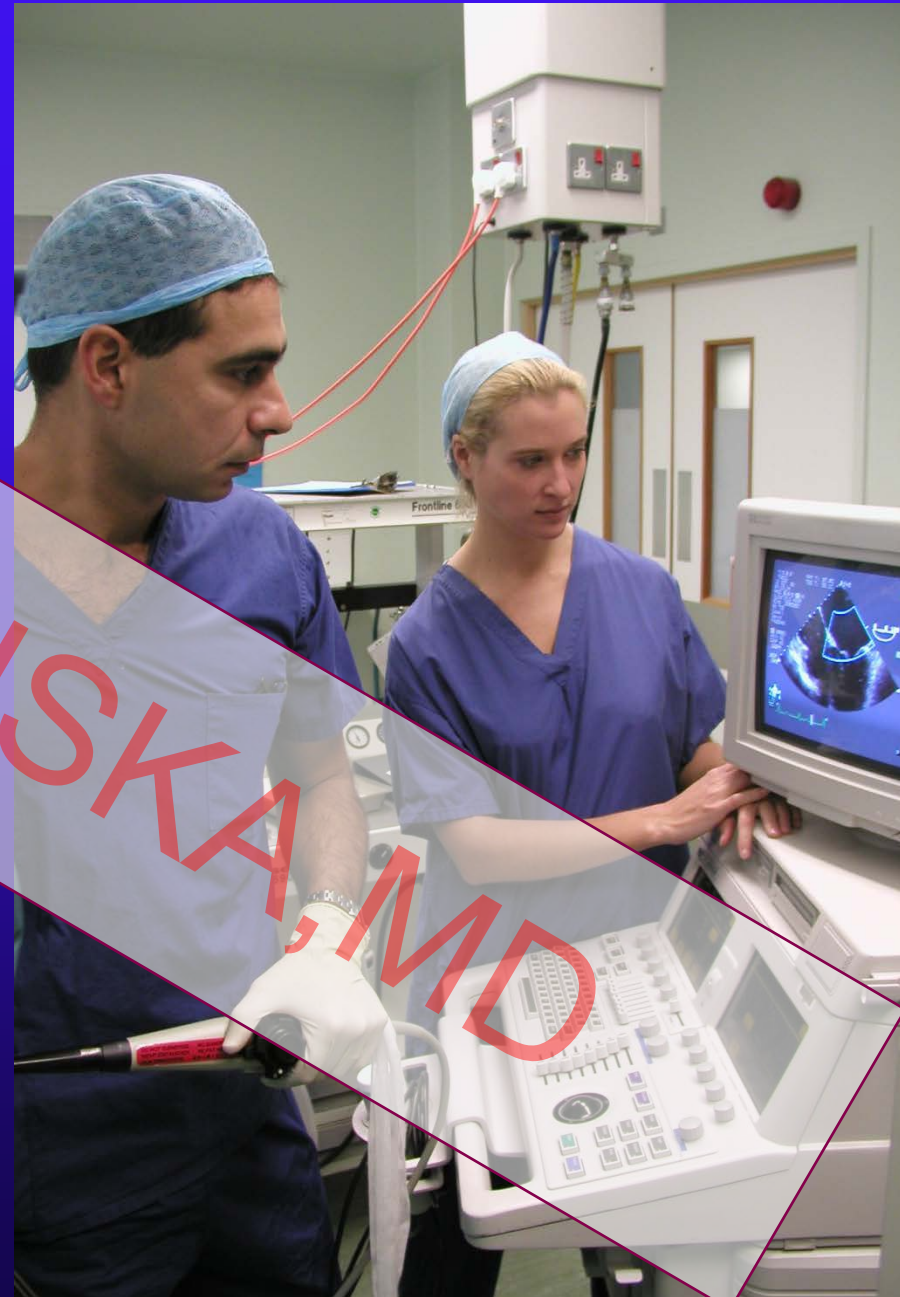Effie Rouska

Glenfield Hospital

University Hospitals of Leicester

## History

- Frazin et al. Circulation 1976;54:102
- Matsumoto et al.  
Am J Cardiol 1980;46:95-105
- Hillel et al.  
J Cardiothorac Anesth 1988;2:803
- now standard of care
  - valve repair, CHD
  - extensively used
  - 1200 certified anaesthetists in USA
  - ACTA/BSE Accreditation

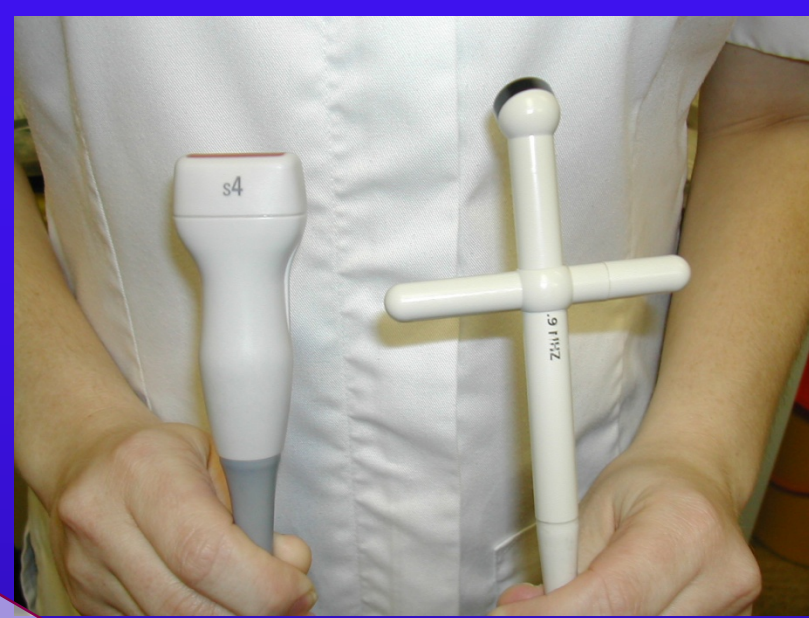


# Ultrasound

- frequency  $>20000$  hertz
- wavelength varies
- velocity = function of soft tissue

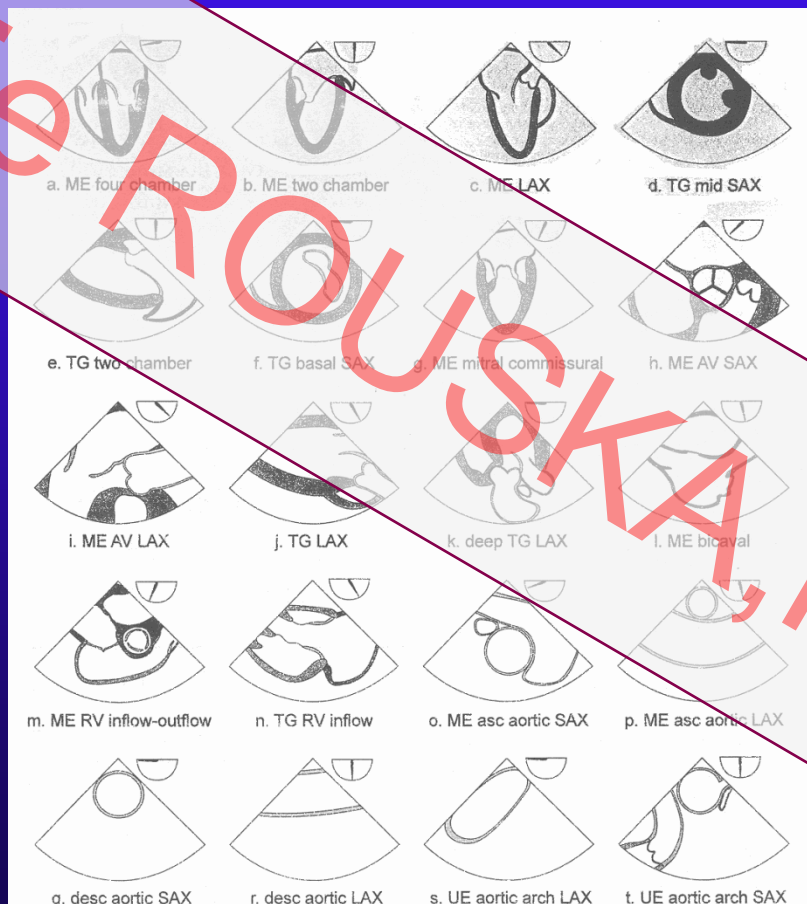
$$v = f \times \lambda \text{ (1540 m/sec)}$$

- higher frequency
  - shorter wavelength
  - better resolution
  - less penetration



# Guidelines for performing a comprehensive intraoperative multiplane TEE examination: Recommendations of the ASE Council on intraoperative echocardiography and the SCA Task Force for certification in perioperative TEE

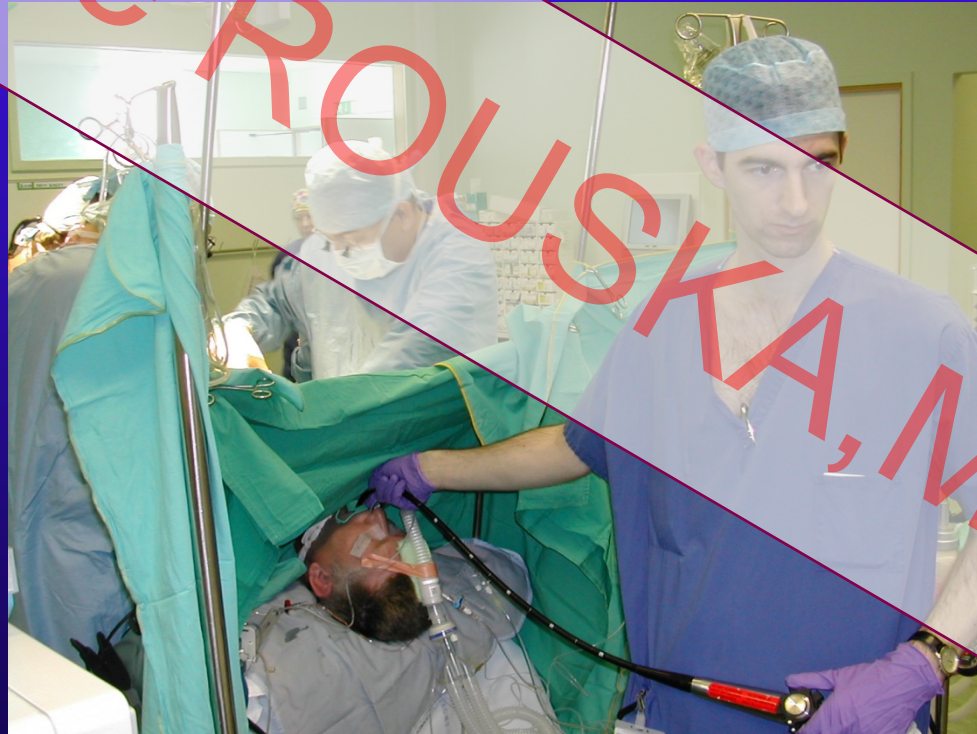Shanewise JS, et al. Anesth Analg 1999;89:870-884



ALSO: Flachskampf FA, et al. Guidelines from the working group: Recommendations for performing transesophageal echocardiography. Eur J Echocardiography 2001;2:8-21

## Why a complete examination?

- Increased practice when learning
- Increased exposure to normal / abnormal anatomy
- Provides baseline for later comparison
- Often unexpected, important findings




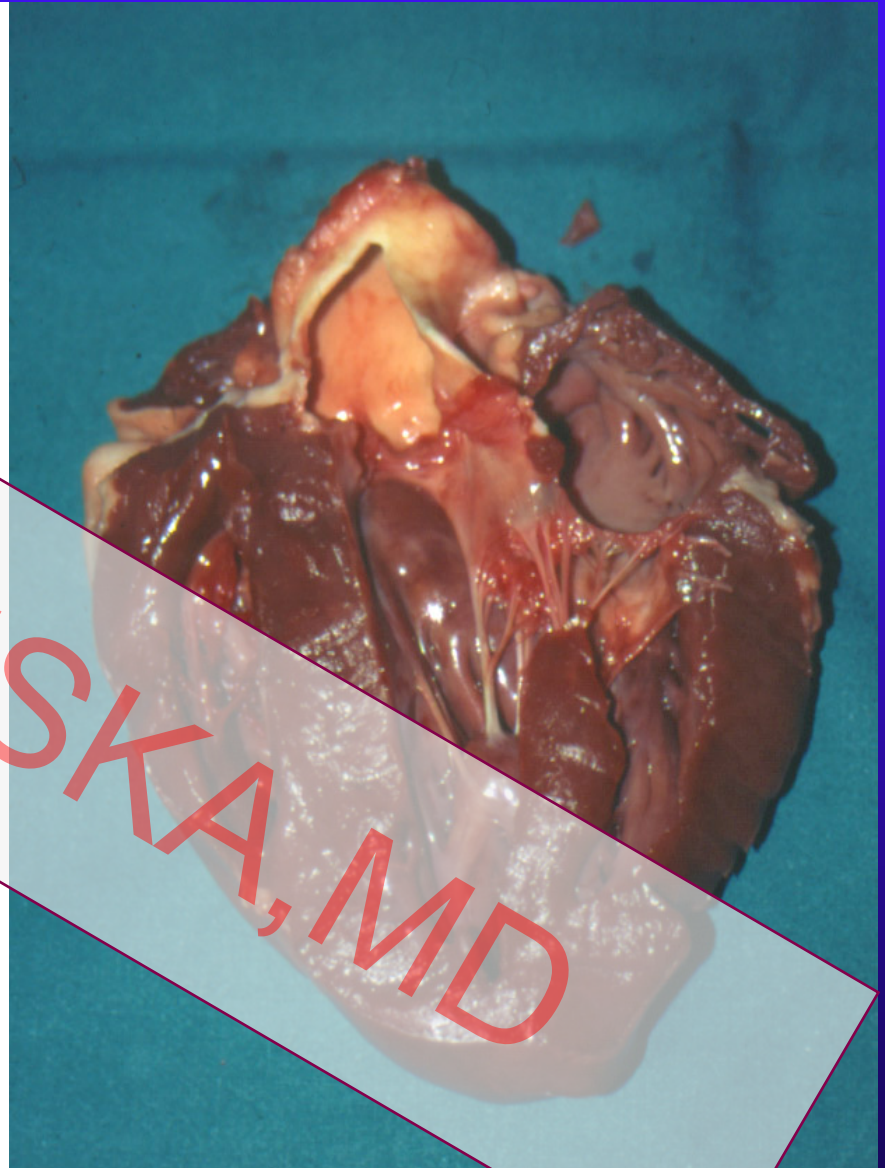
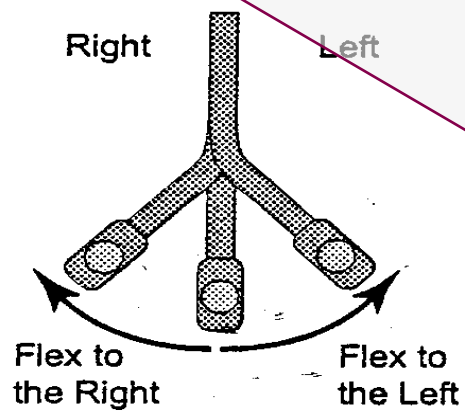
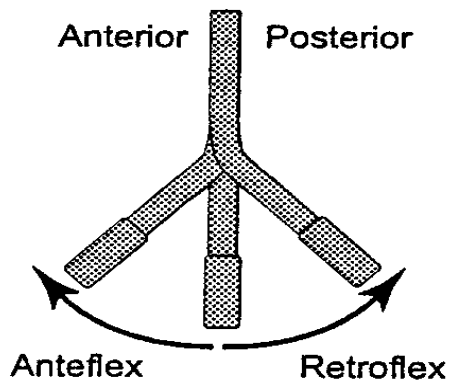
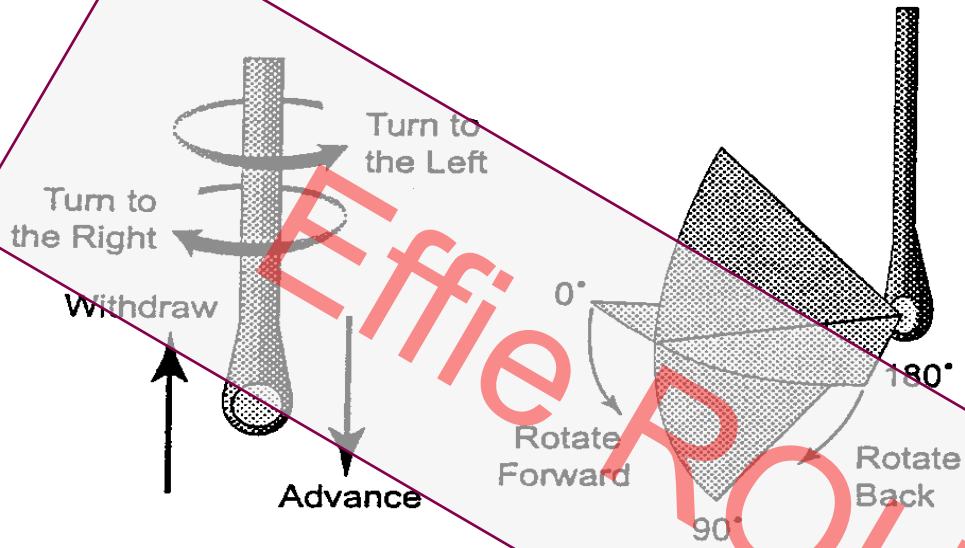
The goal is not to obtain all 20 views in all patients

**Upper oesophageal**

**Mid oesophageal**

**Transgastric**



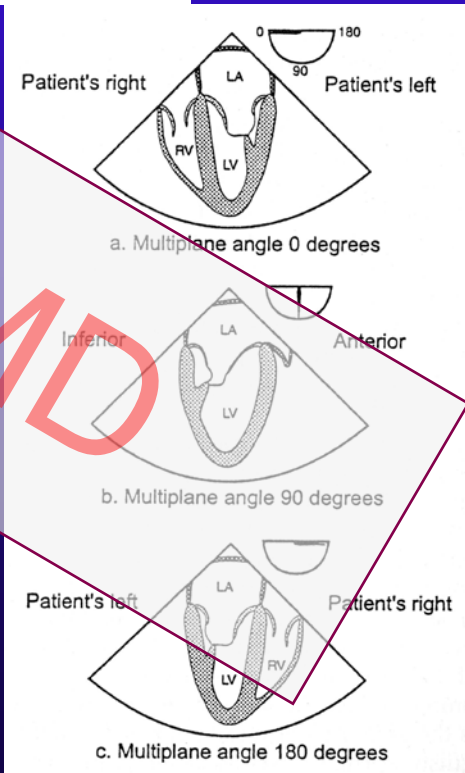
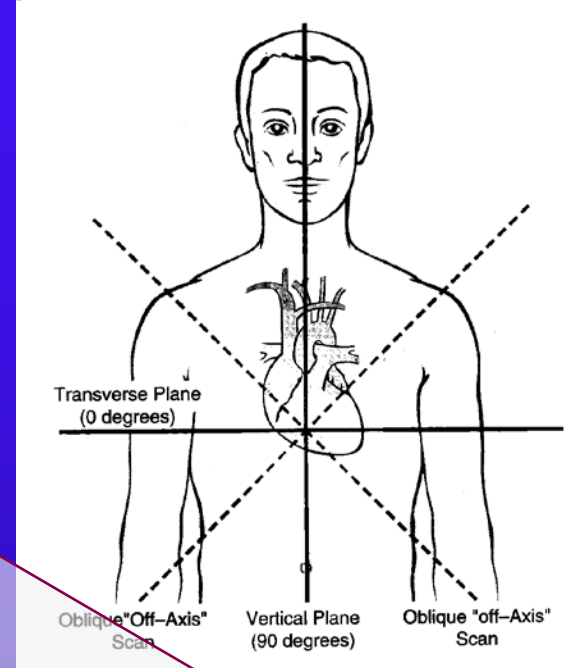


# Planes

- Horizontal plane (0 degrees)  
single plane, transverse plane  
probe depth, flexion-extension
- Vertical plane (90 degrees)  
sagittal plane, longitudinal imaging plane  
probe depth, clockwise, counter-clockwise
- Multiplane “off-axis” imaging (0-180 degrees)


# Axes

- Long axis
- Parallel to major axis of LV
- Short axis
- Perpendicular to major axis of LV

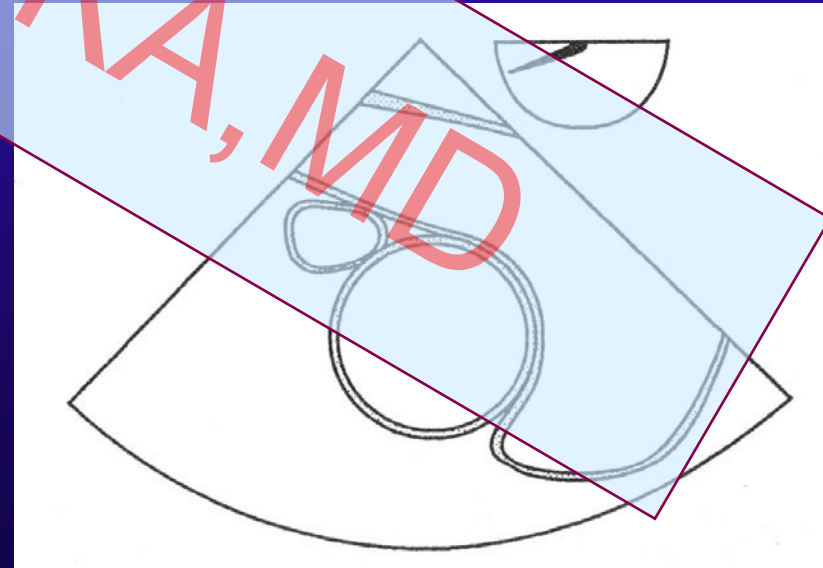
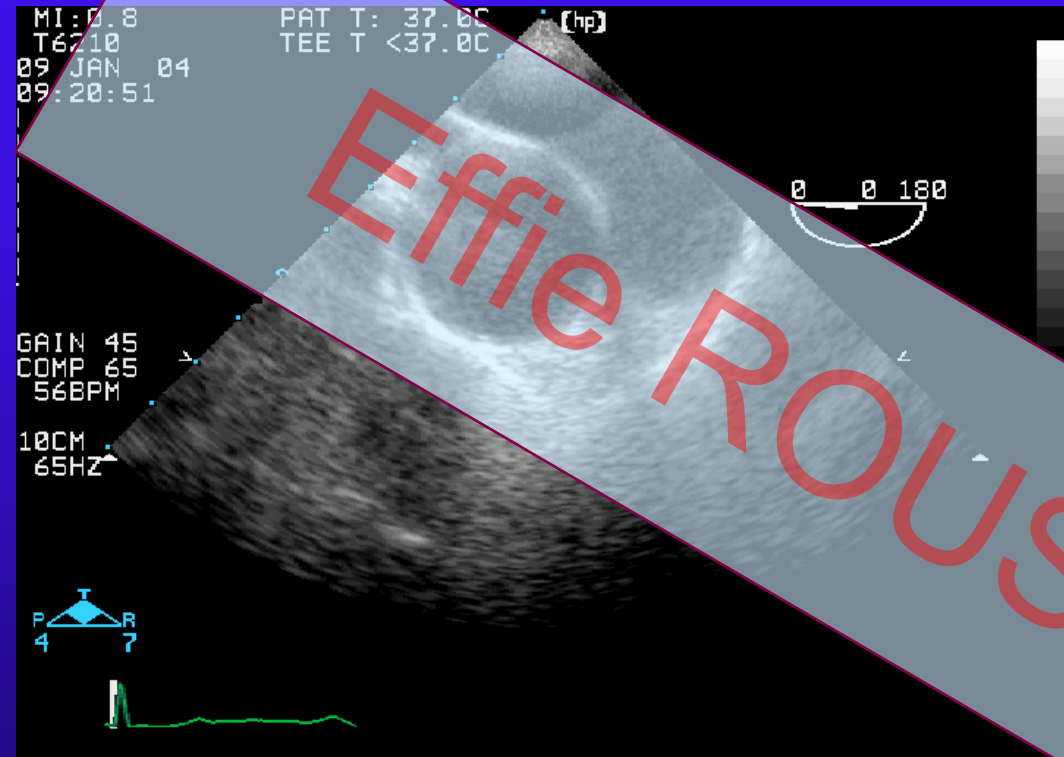




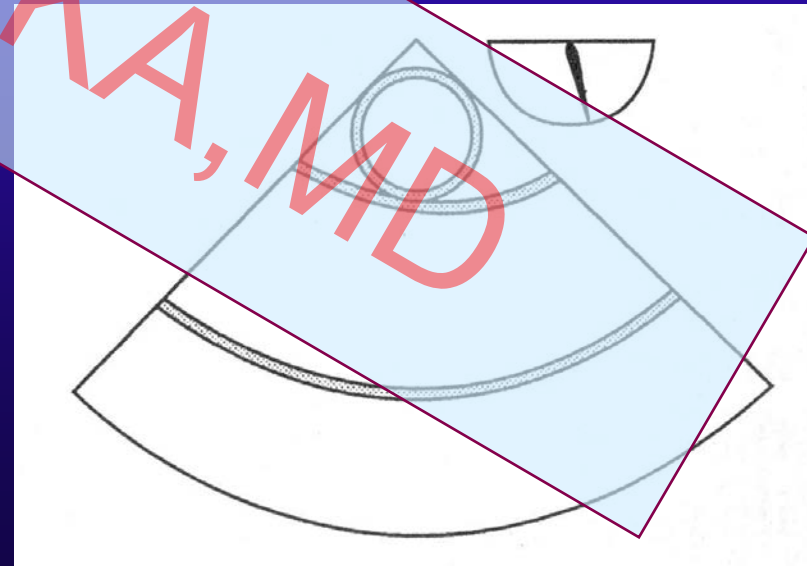
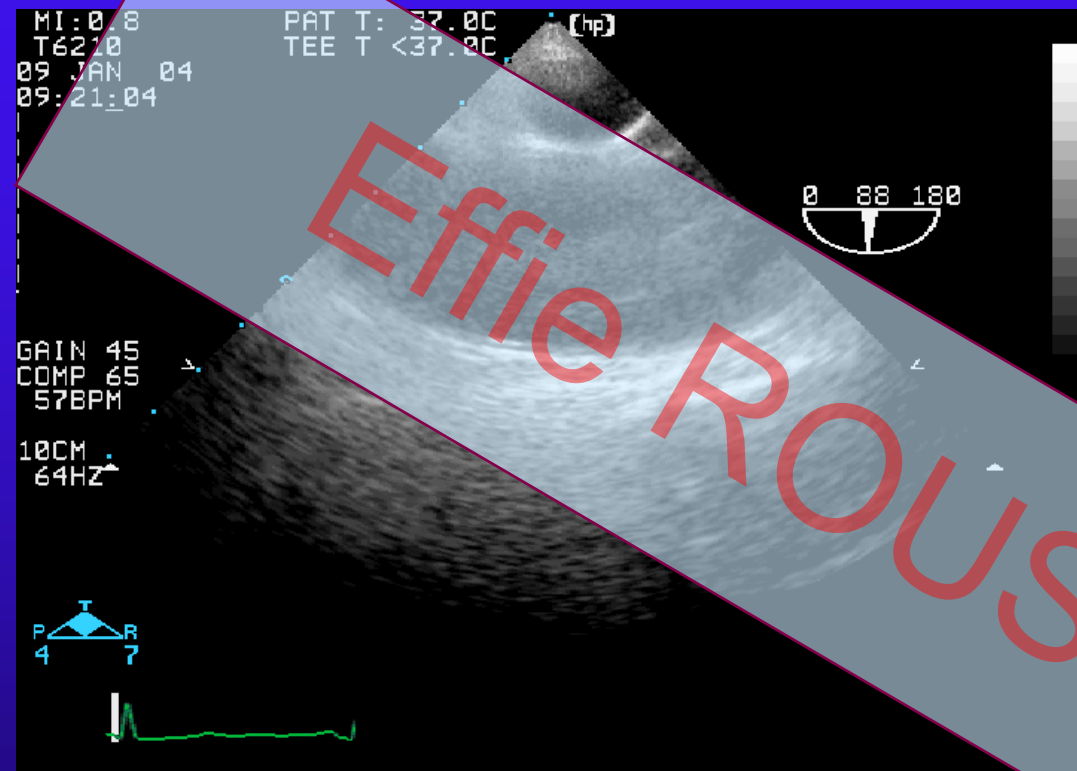
Upper oesophageal



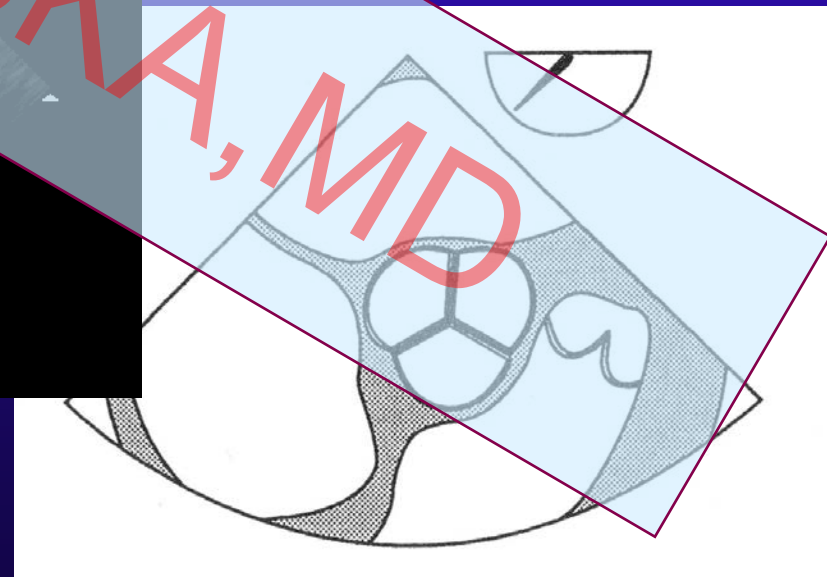
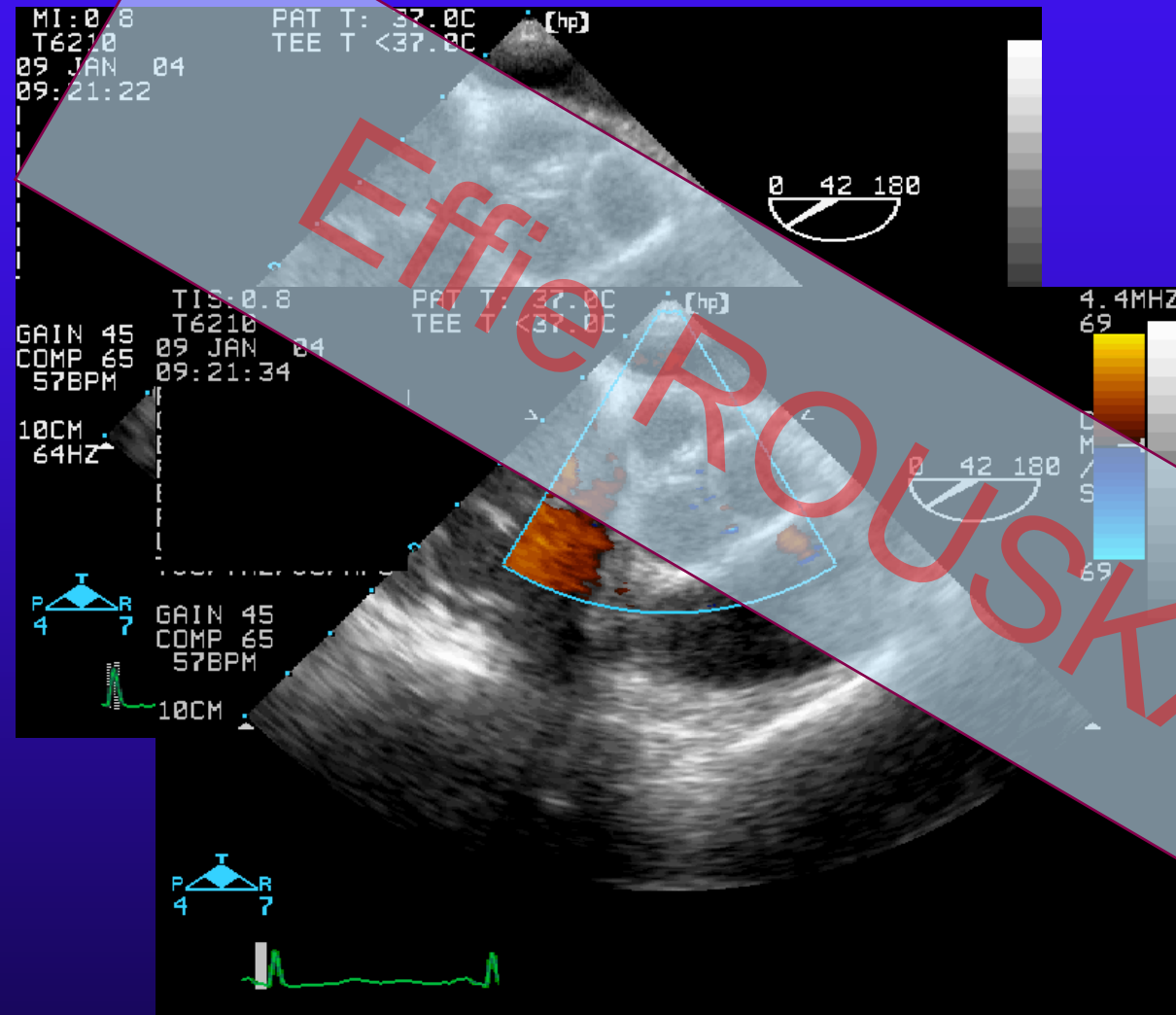
# Midoesophageal ascending aorta SAX



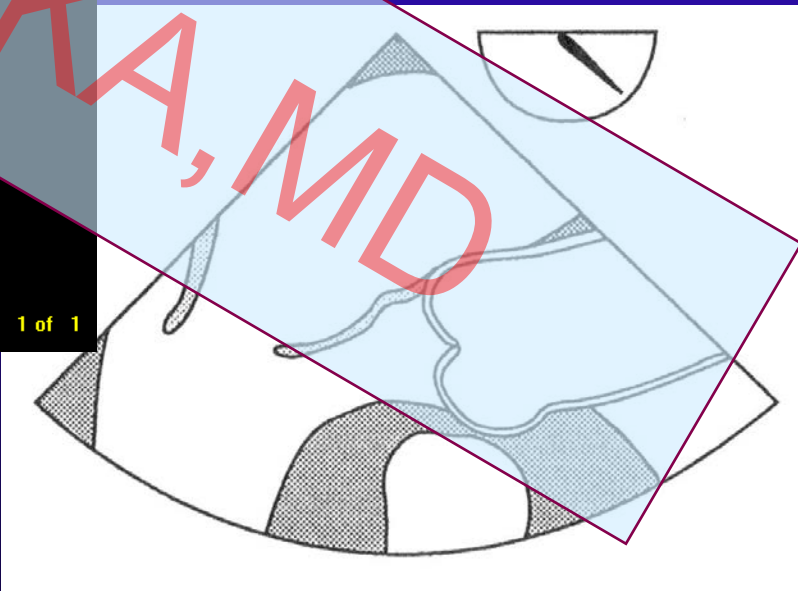
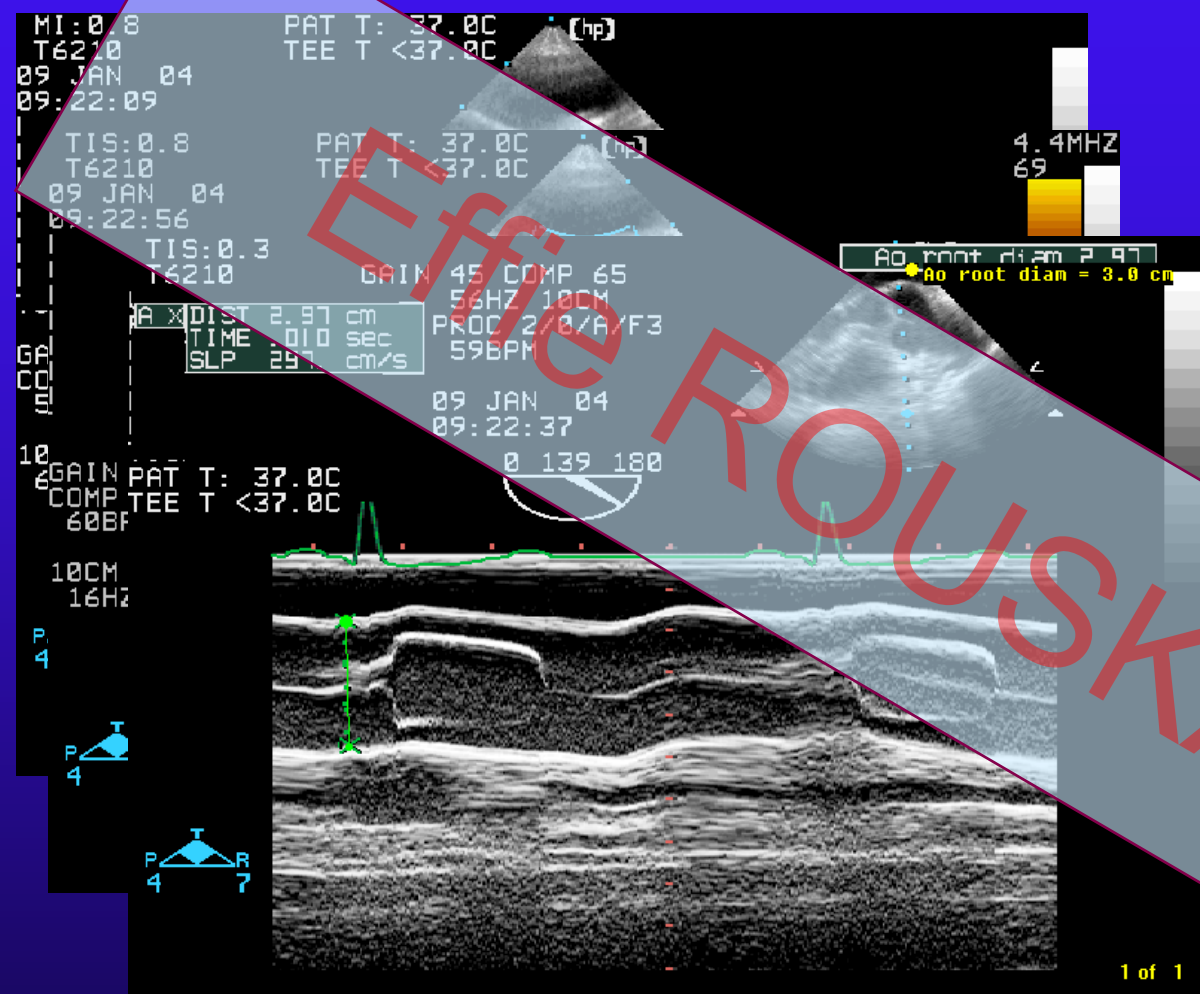
# Midoesophageal ascending aorta LAX




# Midoesophageal AV SAX



# Midoesophageal AV LAX



**Mid oesophageal**

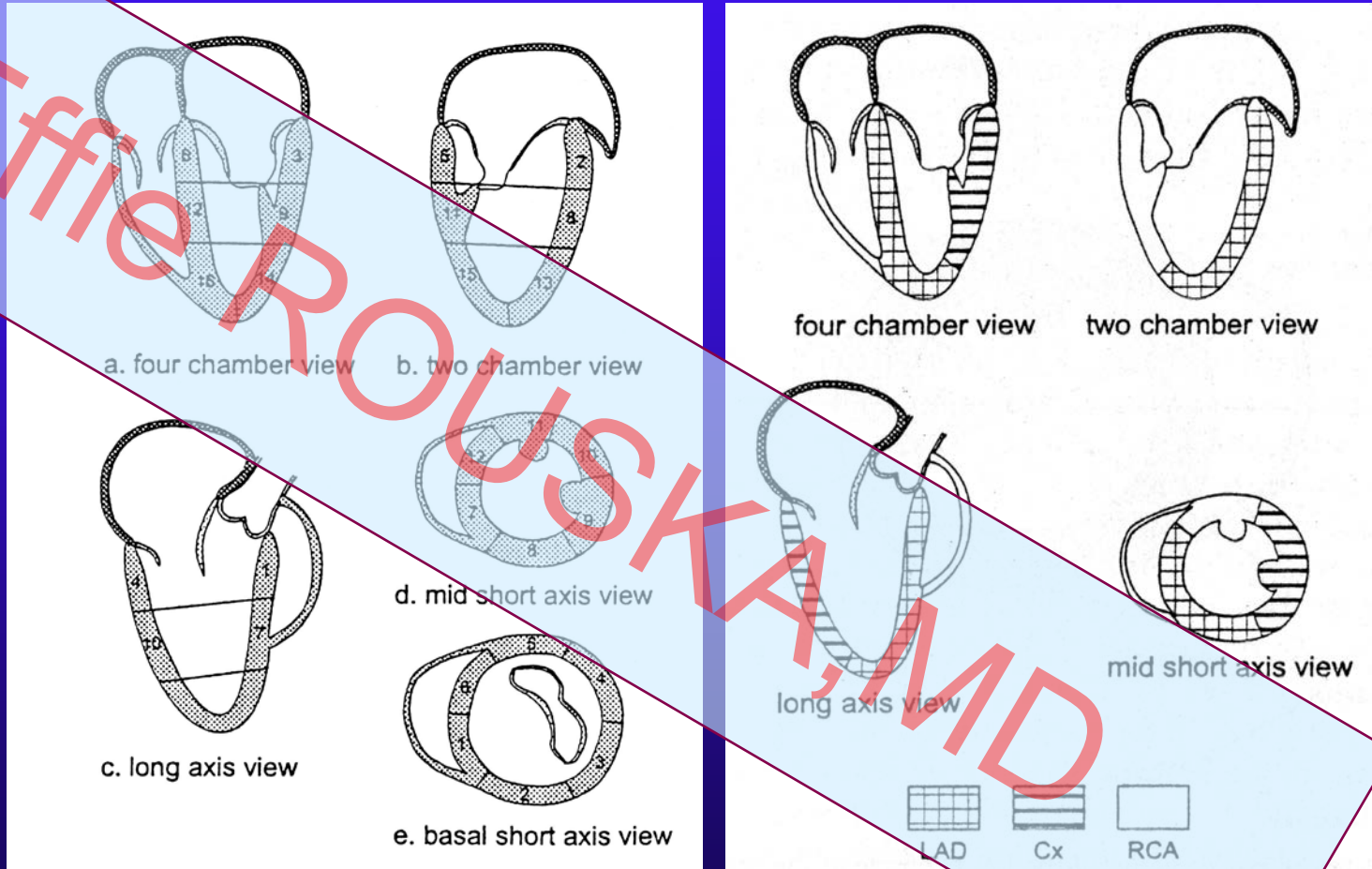


# 16 Segment model of LV

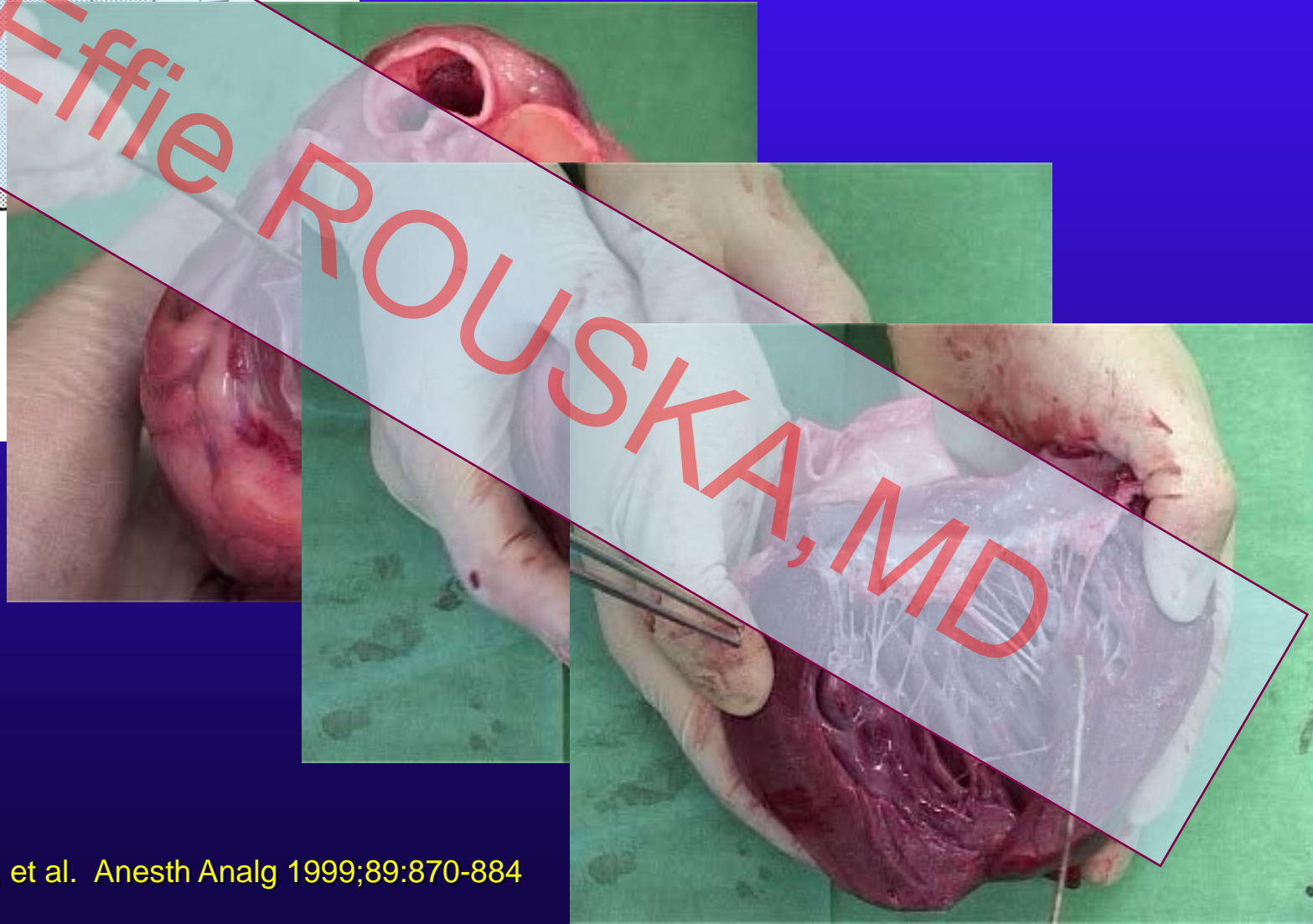
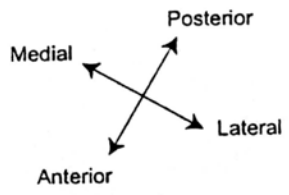
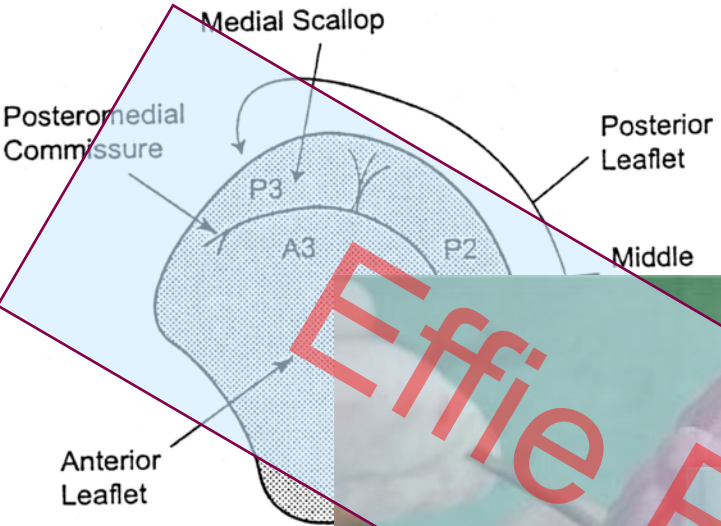
•Basal

•Mid

•Apical

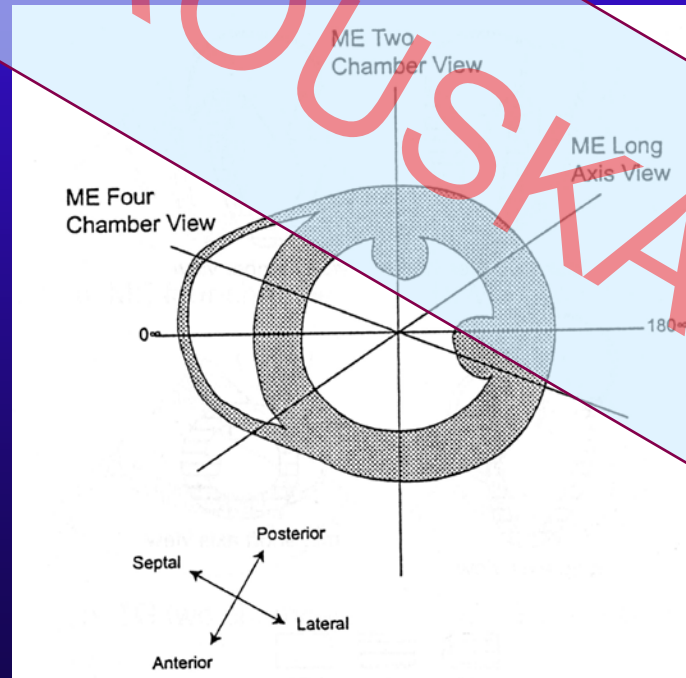
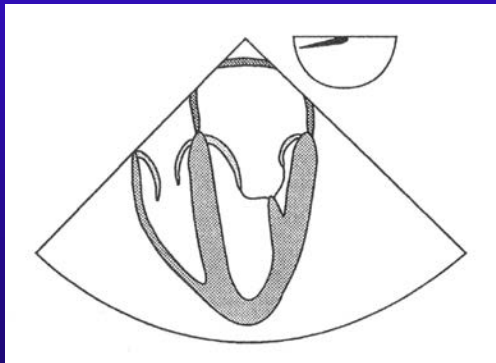
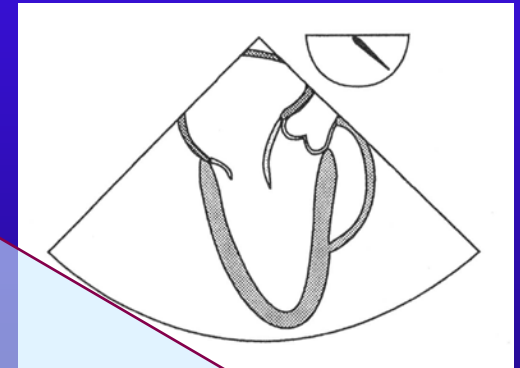
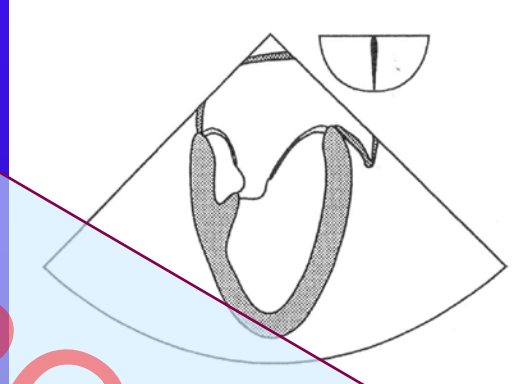



# Mitral Valve

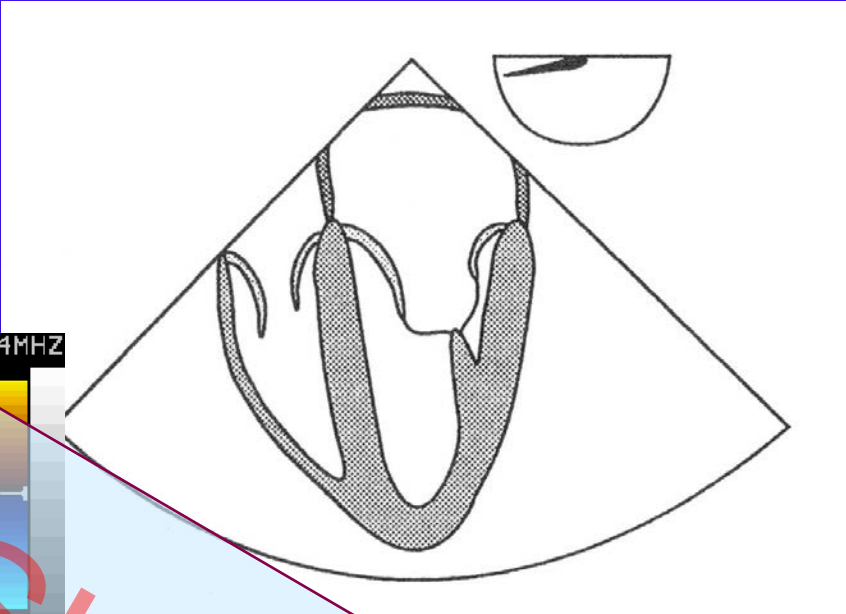
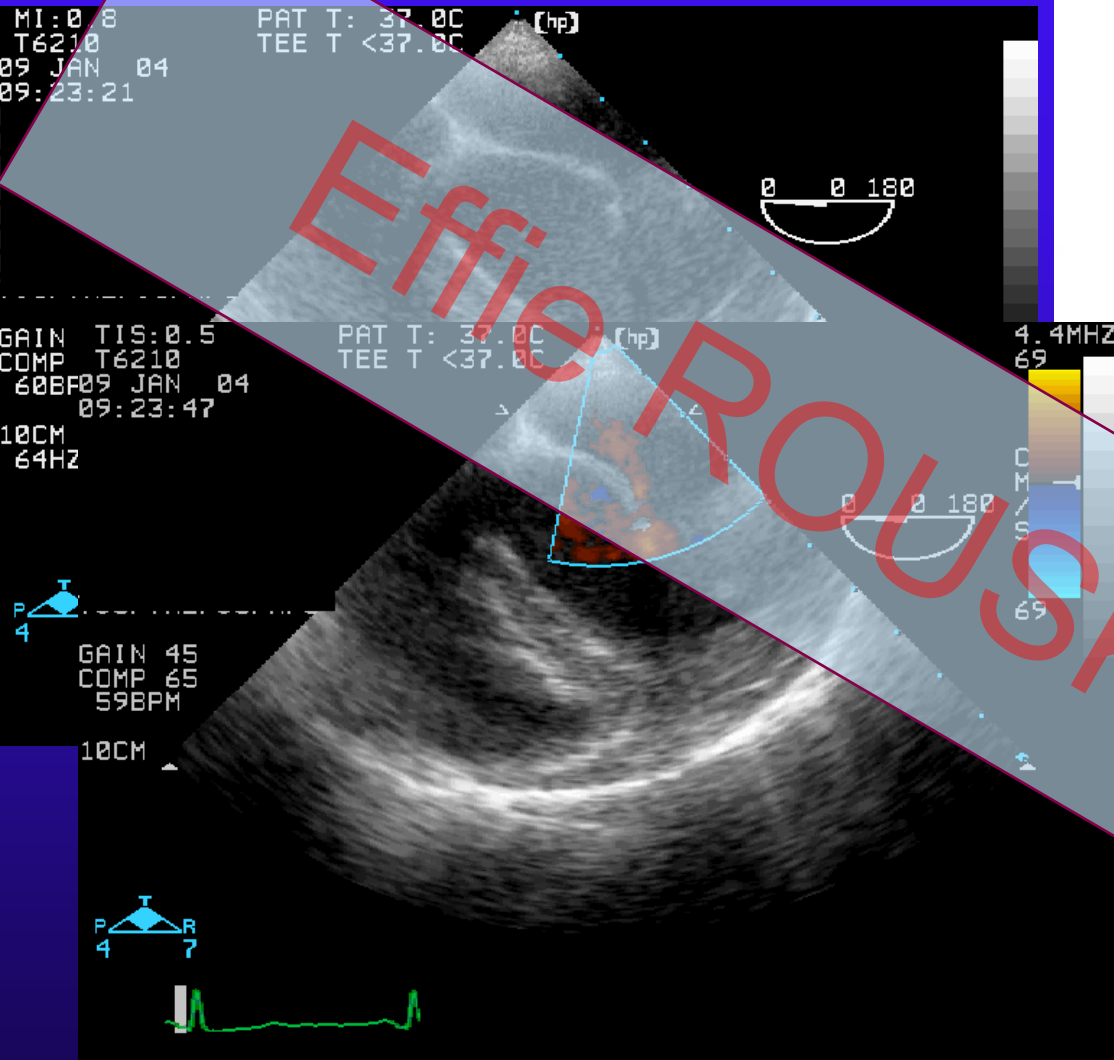




# Midoesophageal LV and MV views




# Midoesophageal 4 chamber



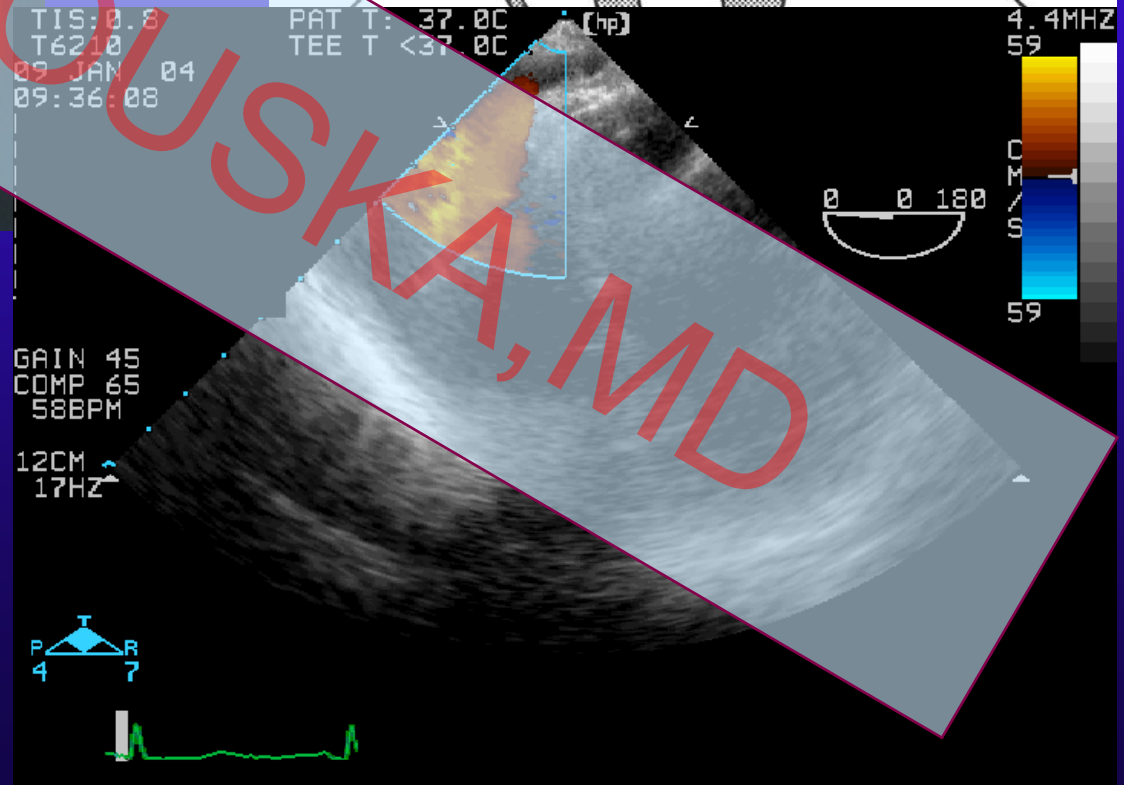
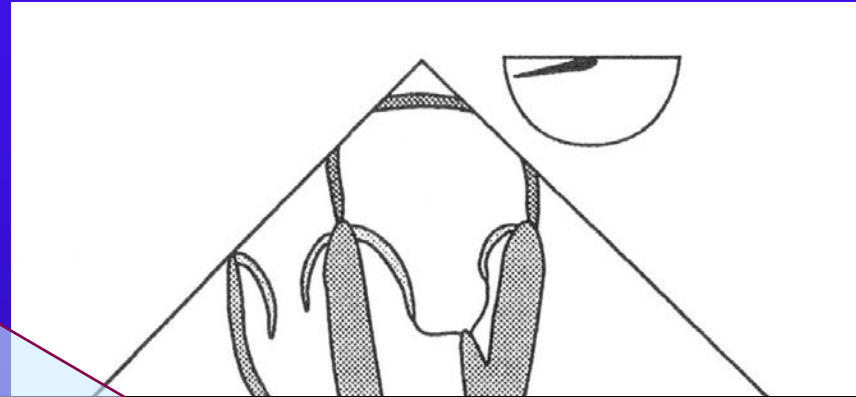
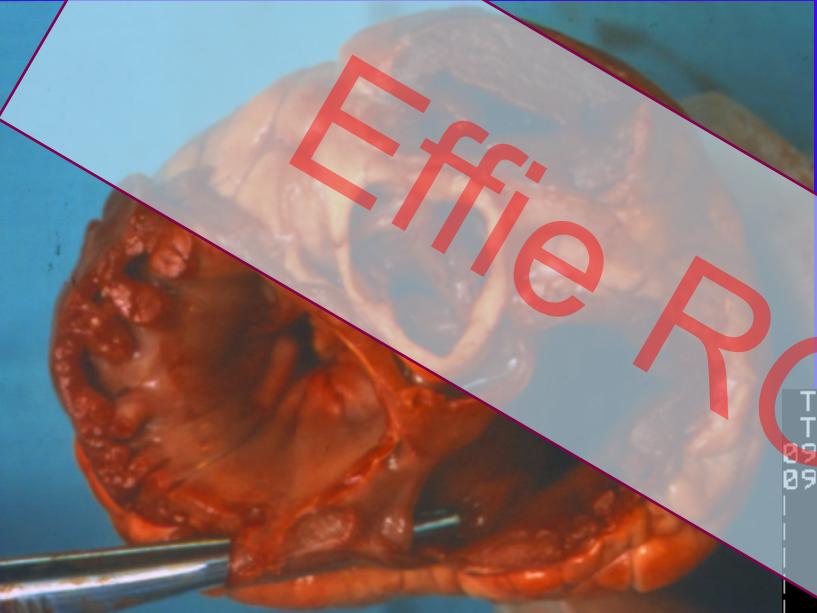Effie ROUSKA, MD

# Midoesophageal 4 chamber – LAA, PV

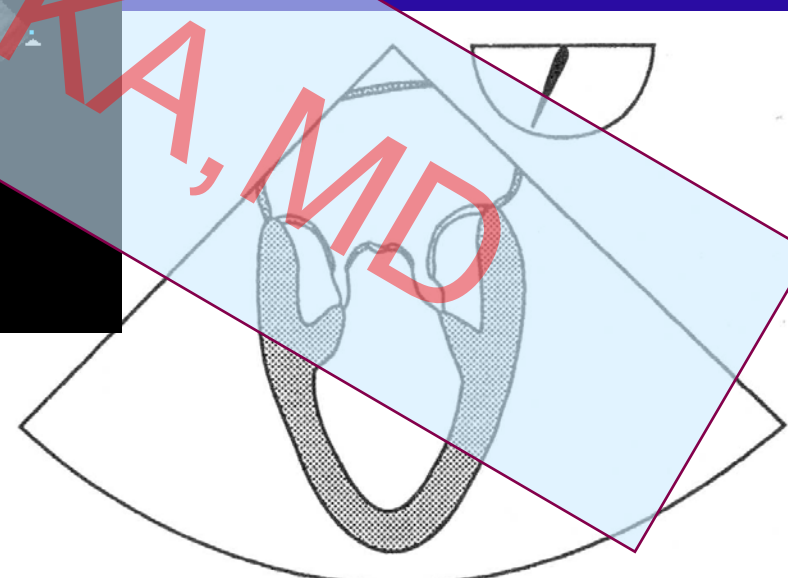
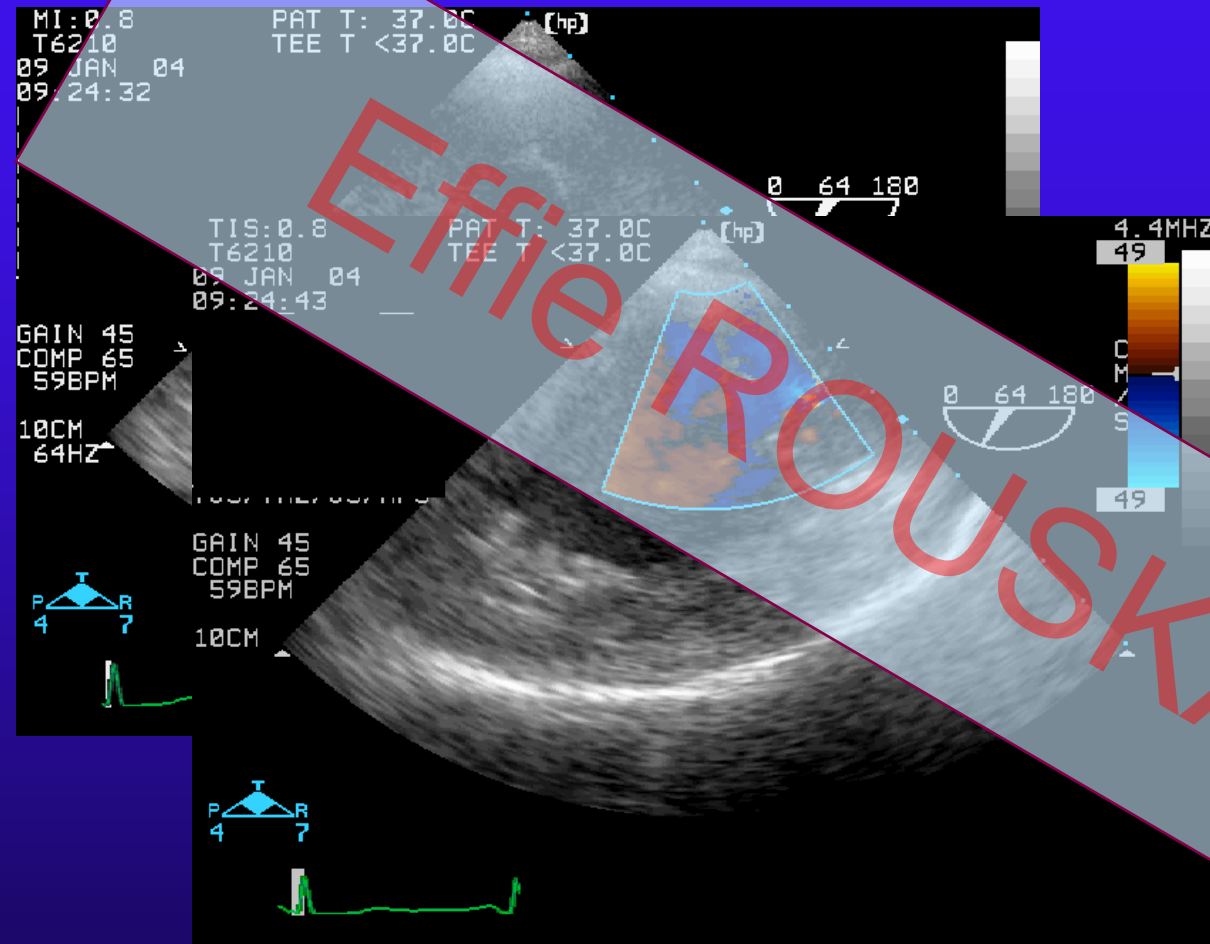


# Midoesophageal 4 chamber – coronary sinus

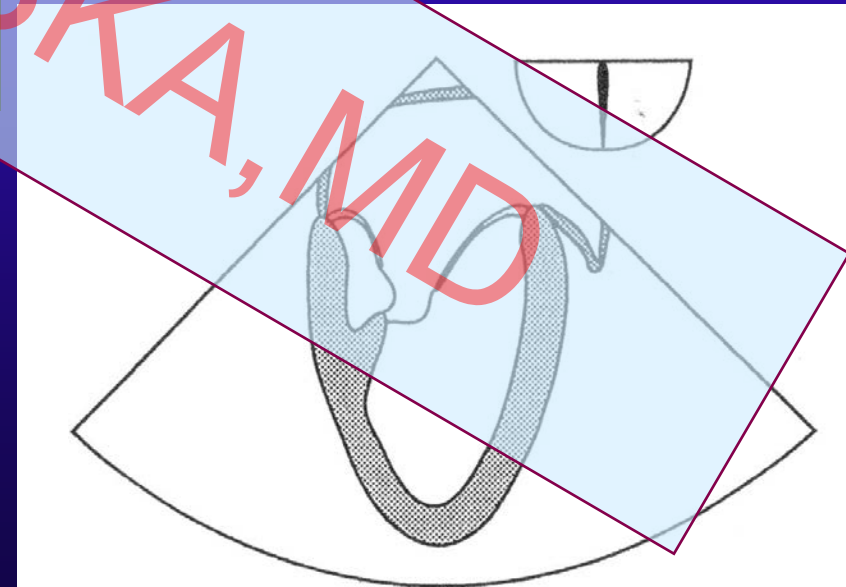
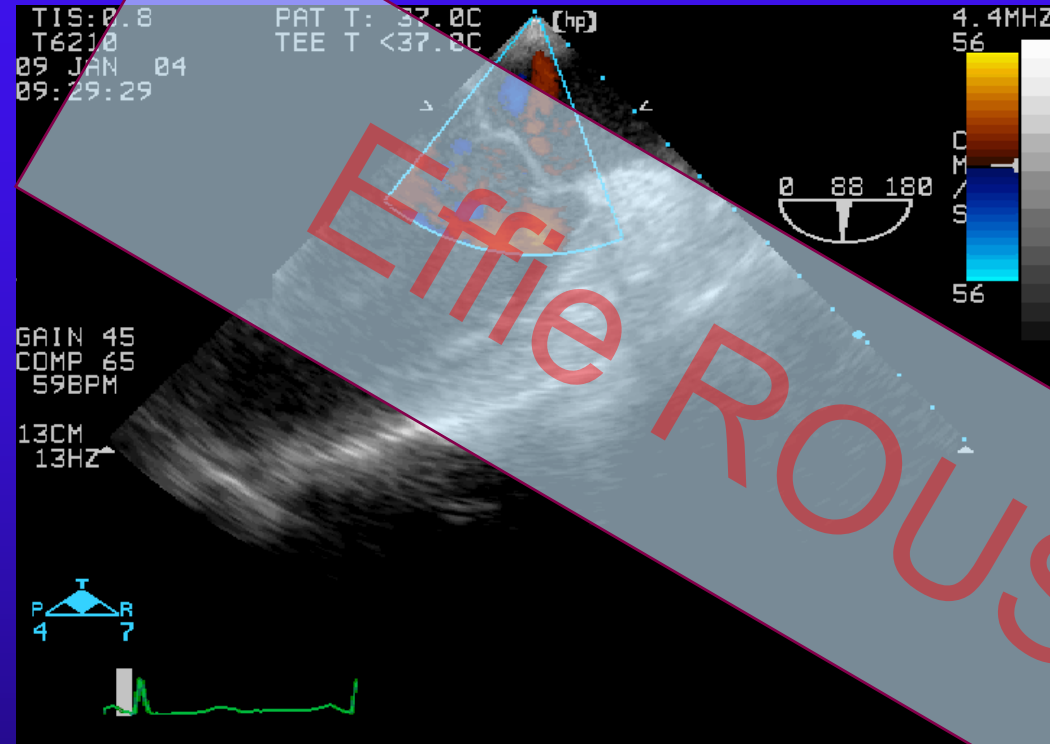
Shanewise JS, et al. Anesth Analg 1999;89:870-884



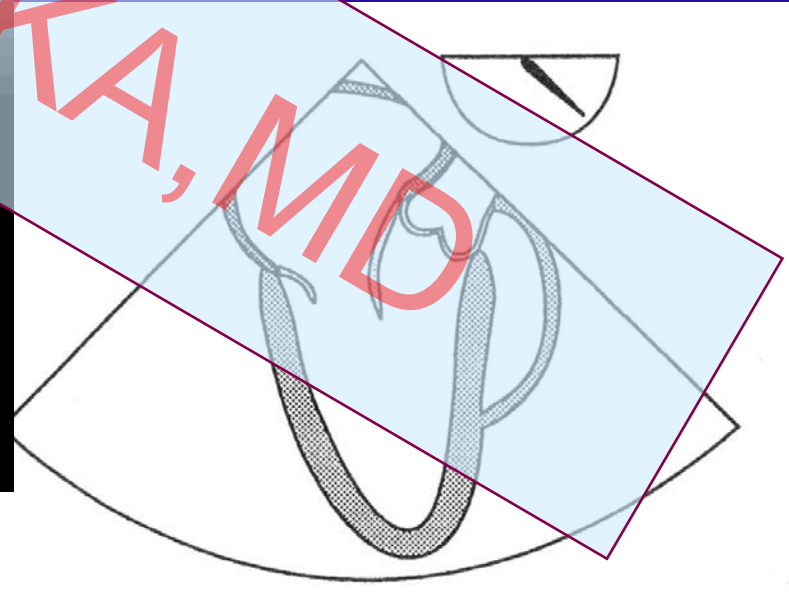

# Midoesophageal commissural view



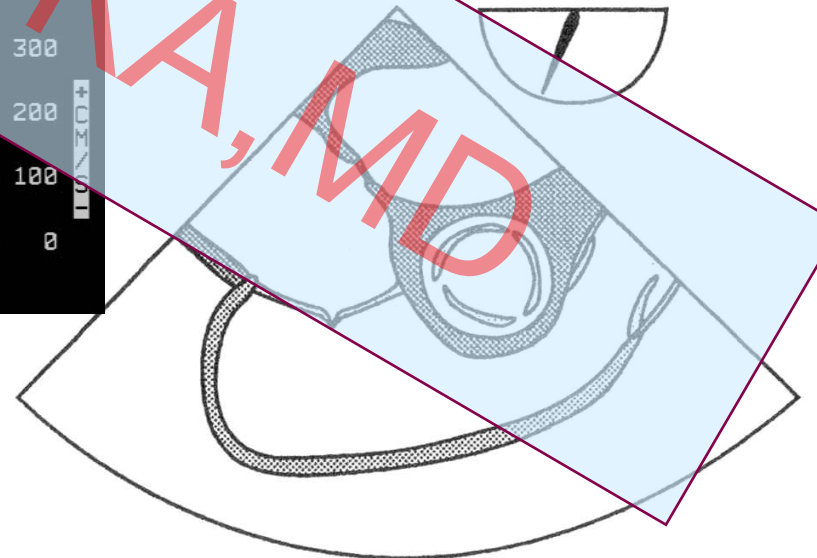

# Midoesophageal 2 chamber view



# Midoesophageal LAX

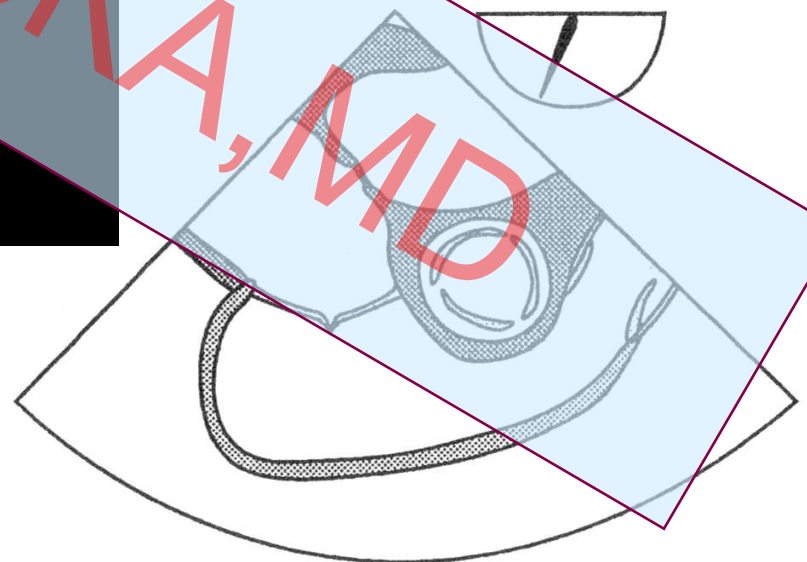
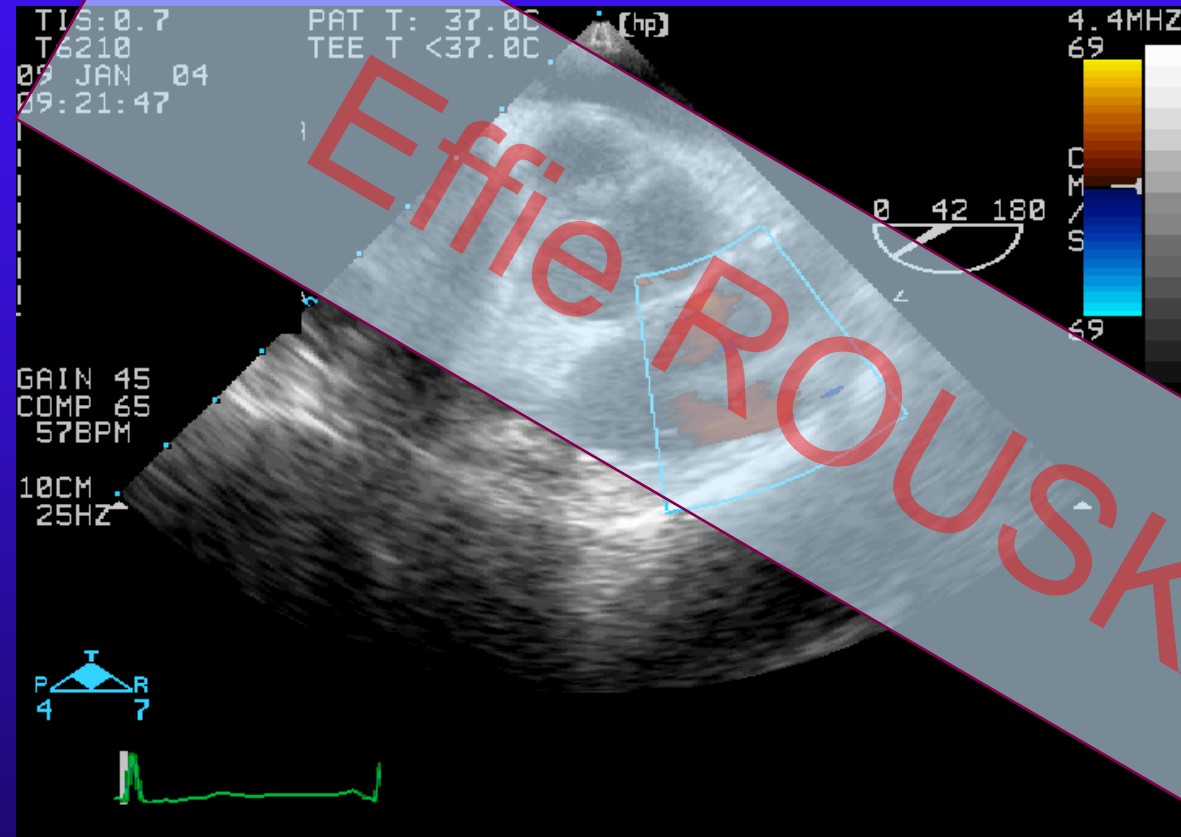


# Midoesophageal RV inflow-outflow

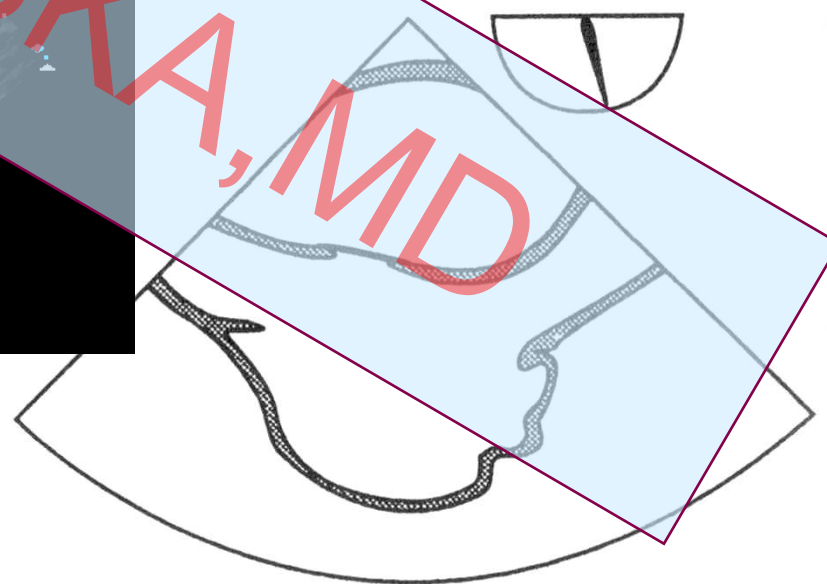
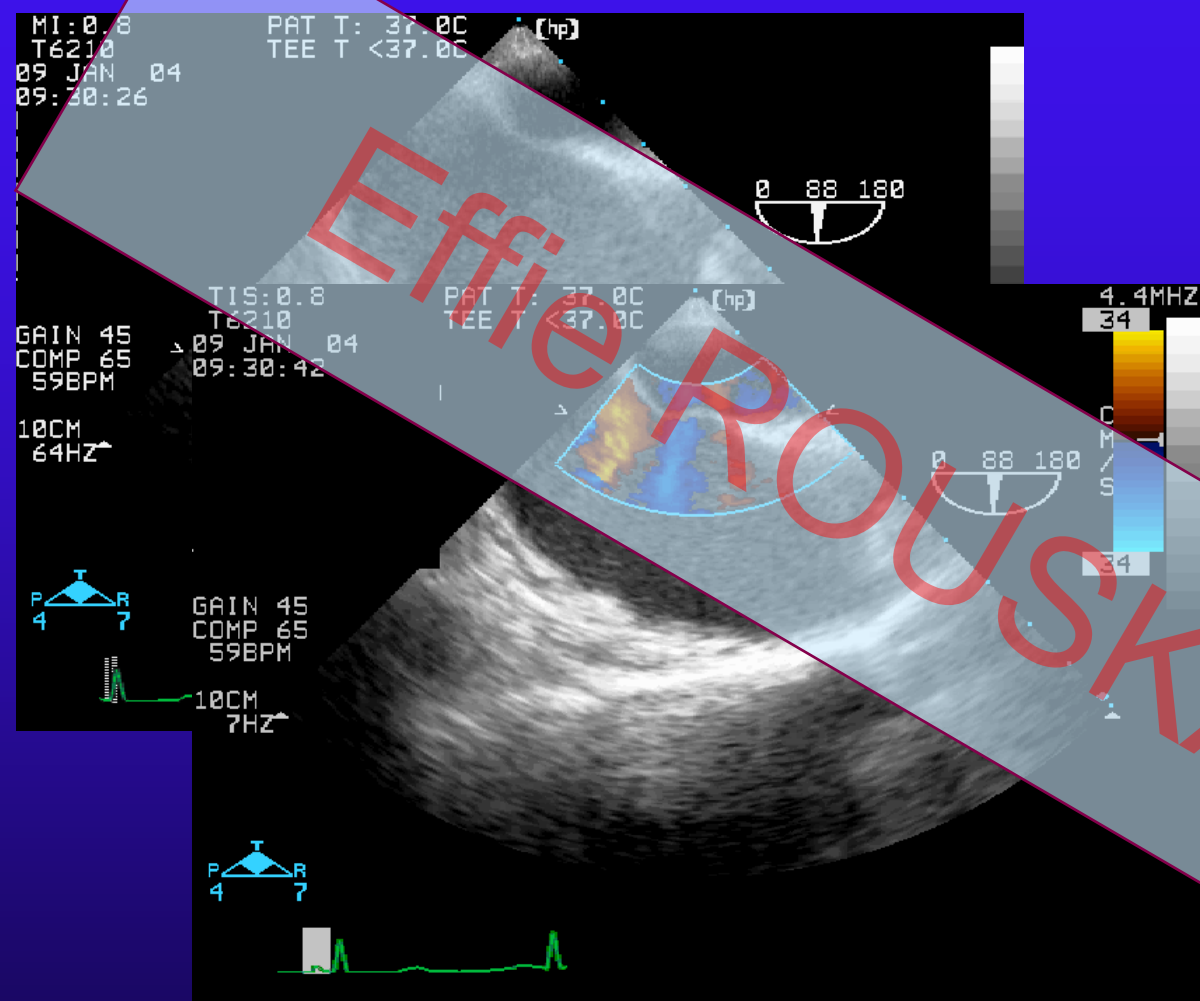




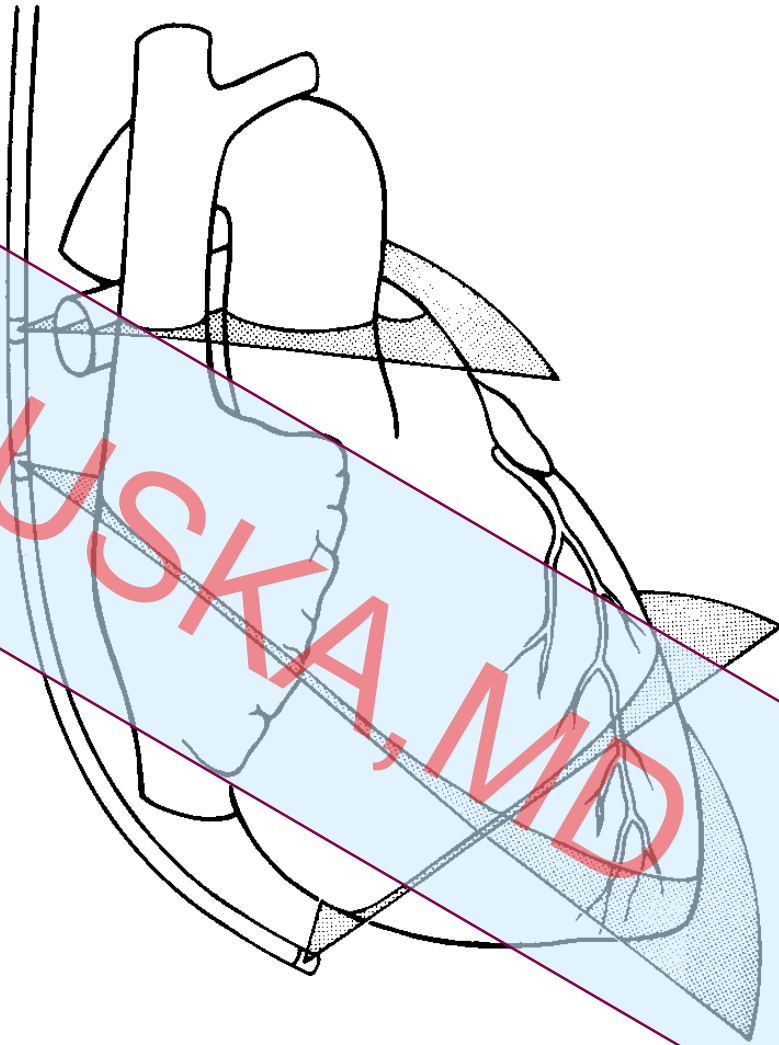
# Midoesophageal RV inflow-outflow



# Midoesophageal bicaval view

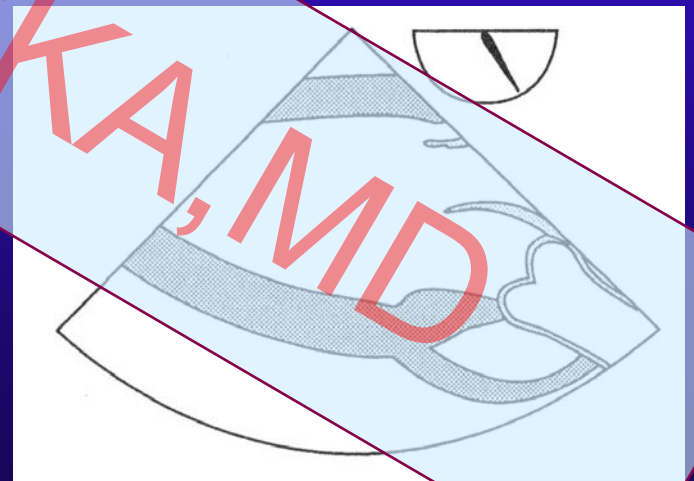
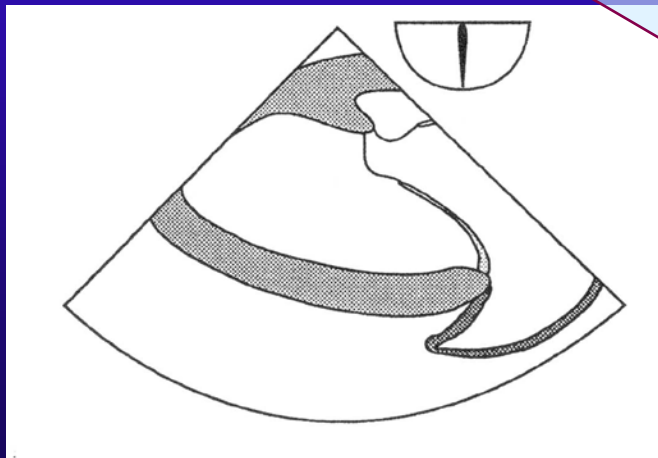
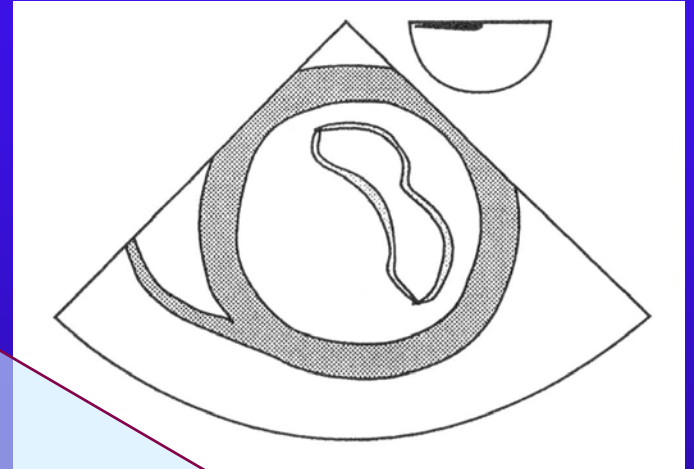
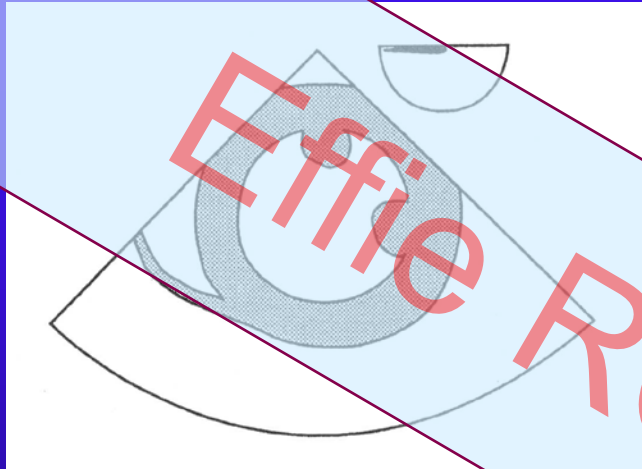


Effie ROUSKA, MD

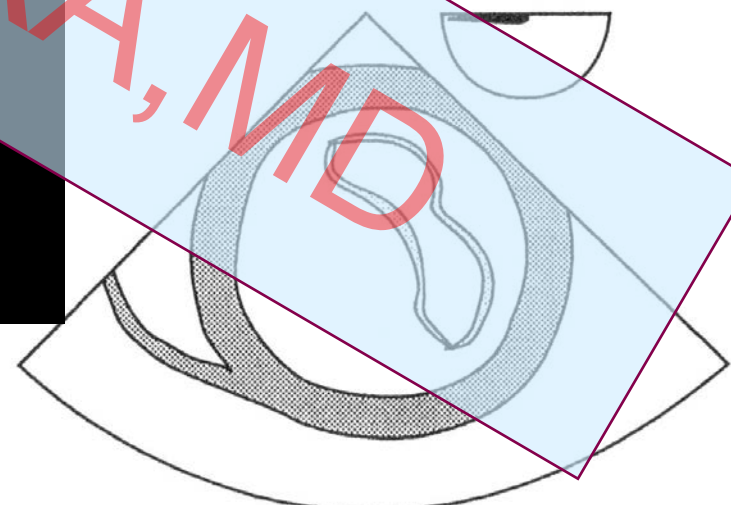
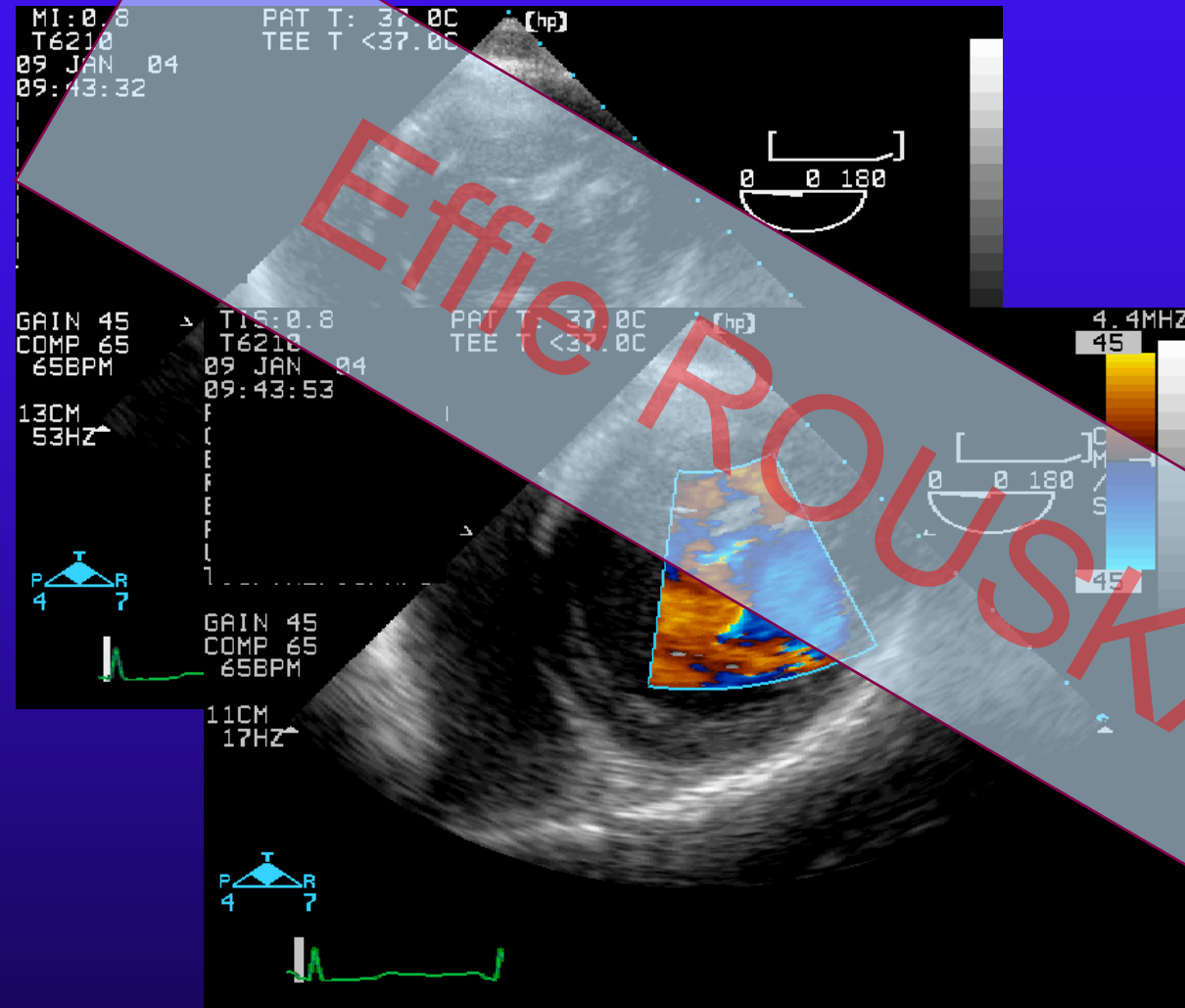


**Transgastric**

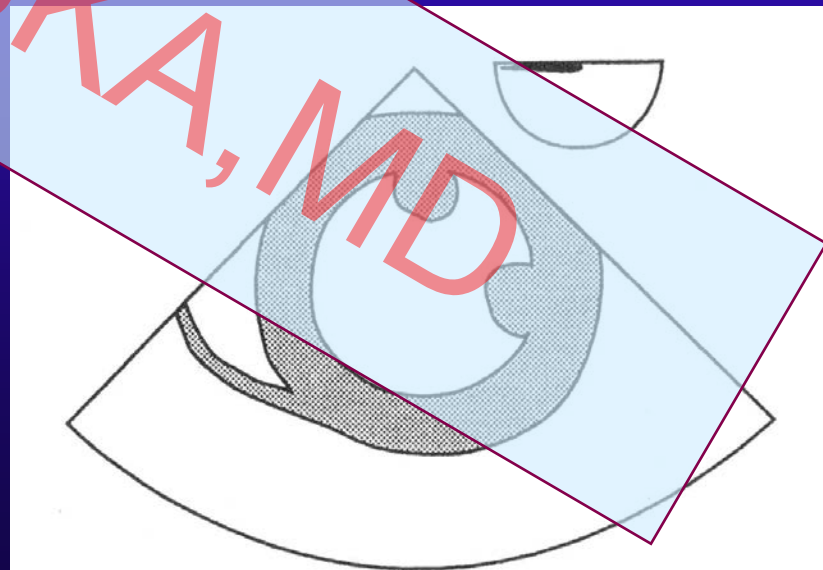
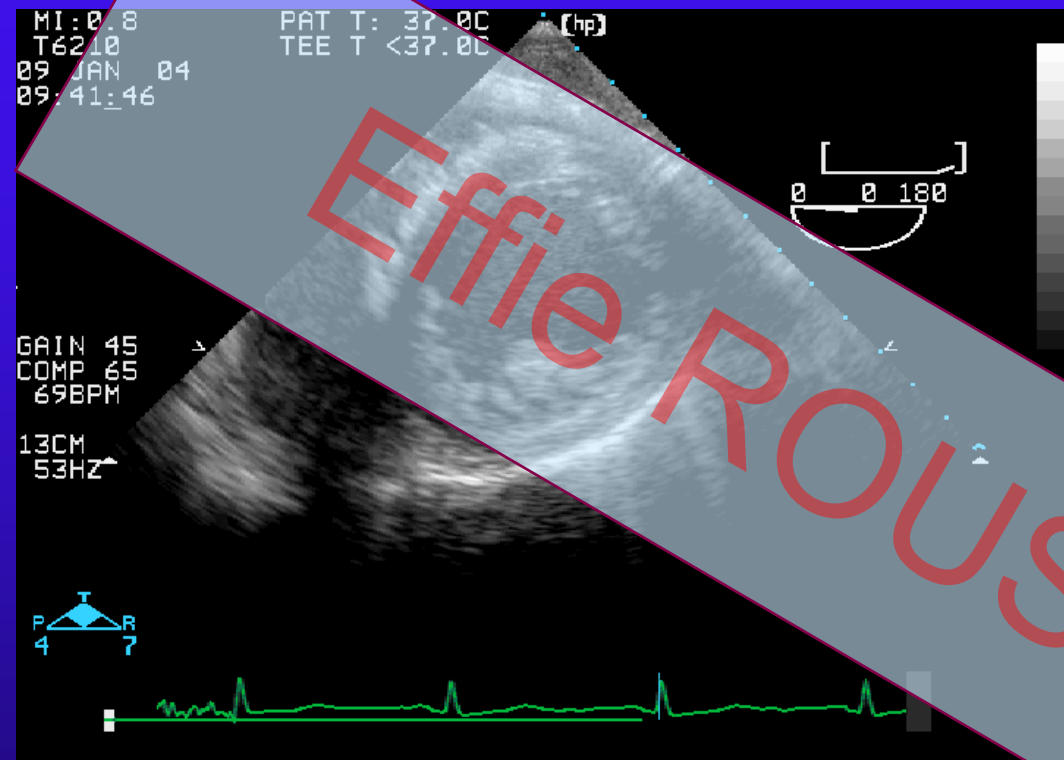
# Transgastric LV function and MV views



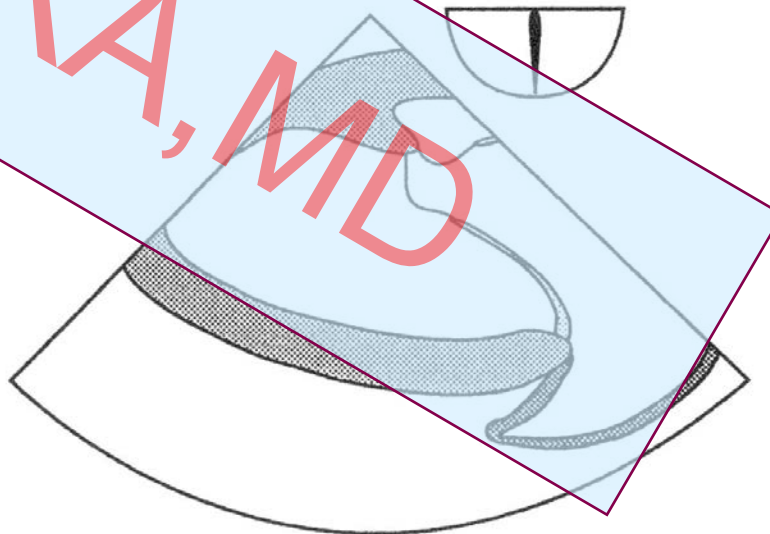
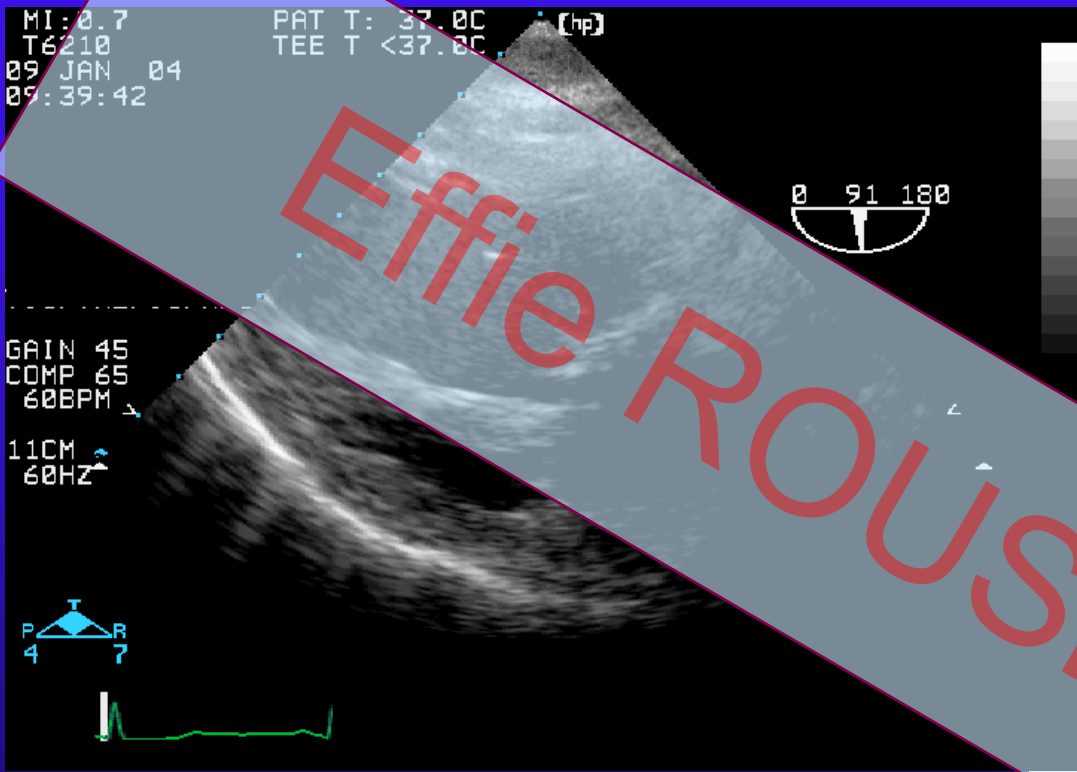
# Transgastric basal SAX



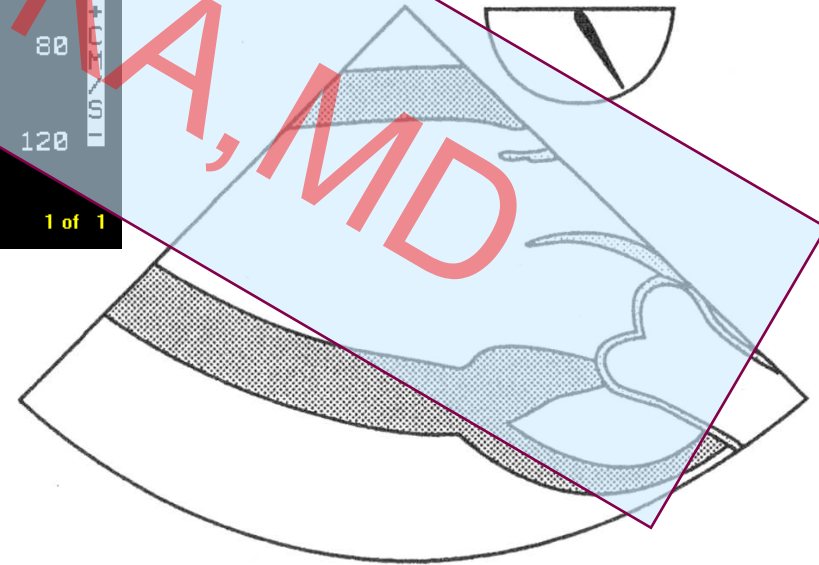
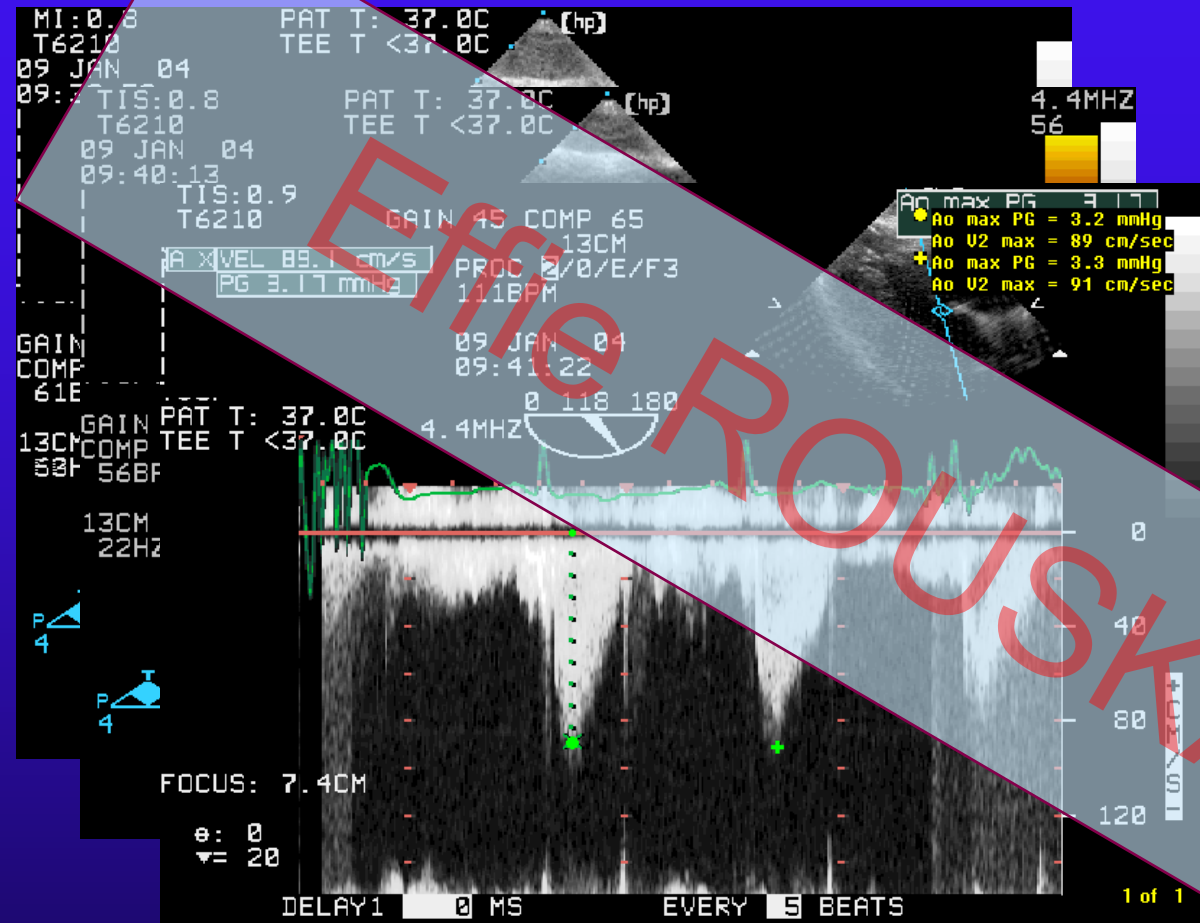
# Transgastric midpapillary SAX



# Transgastric 2 chamber

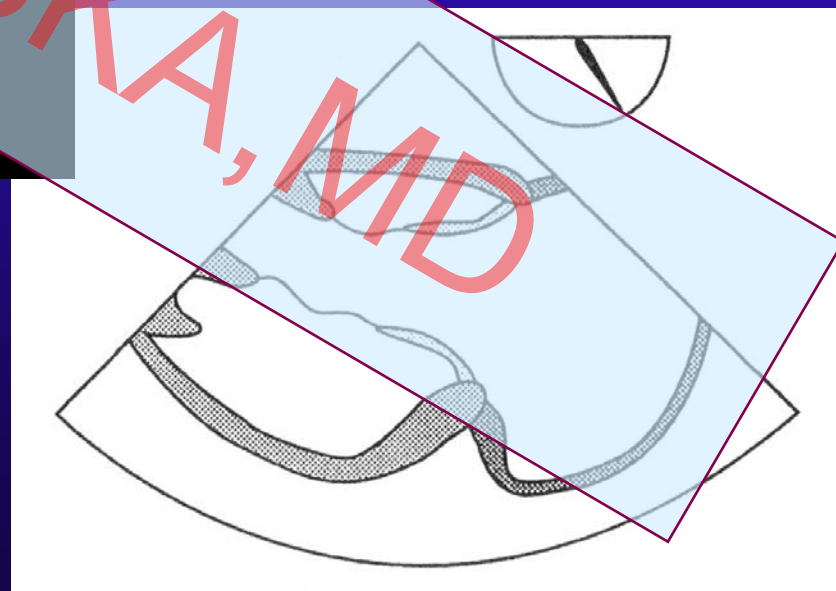
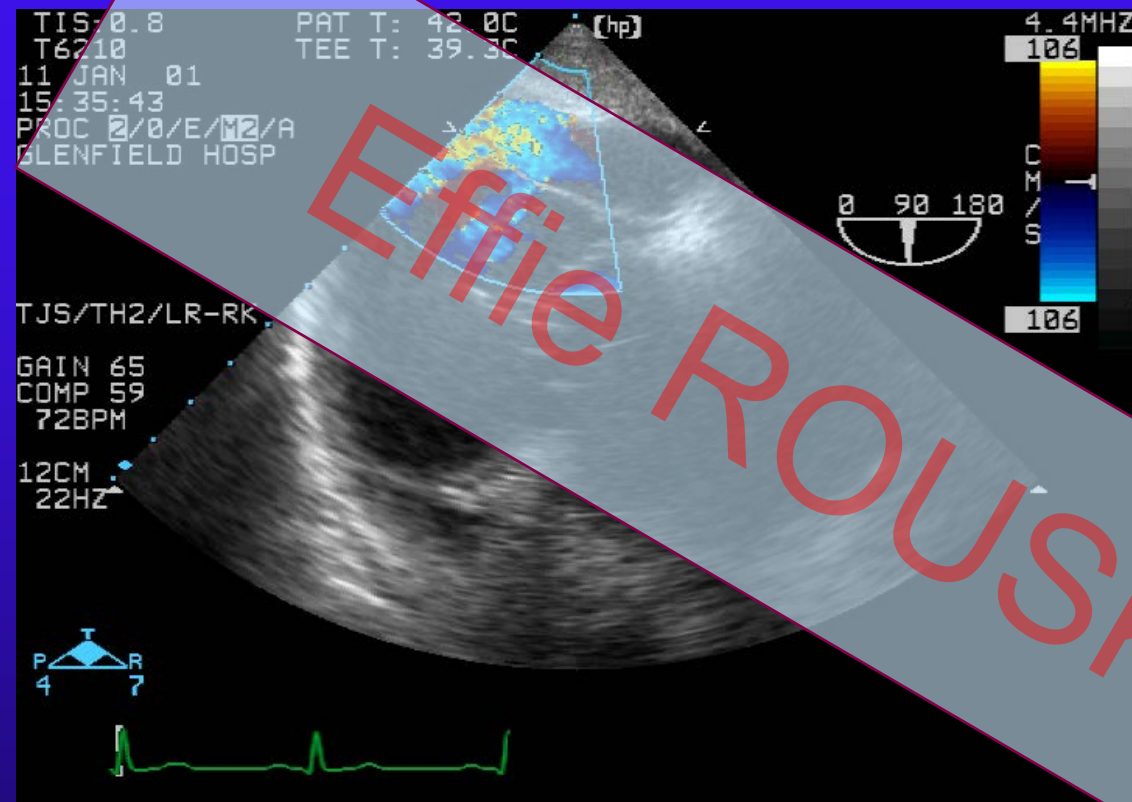


# Transgastric LAX

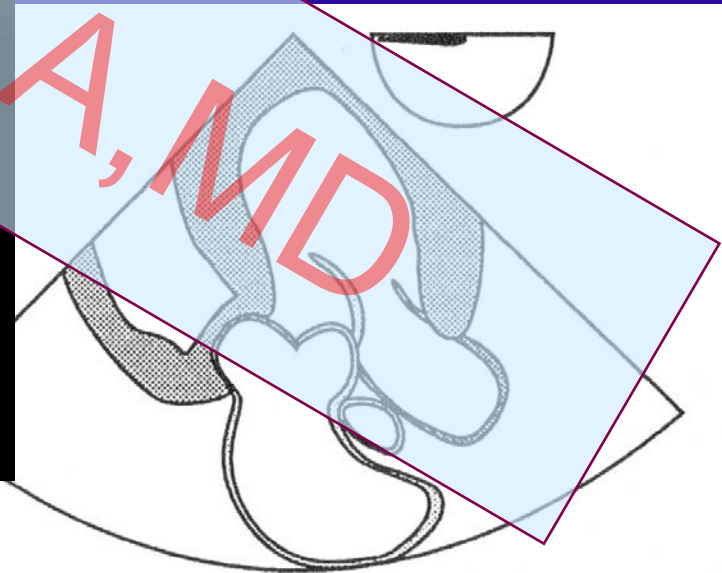





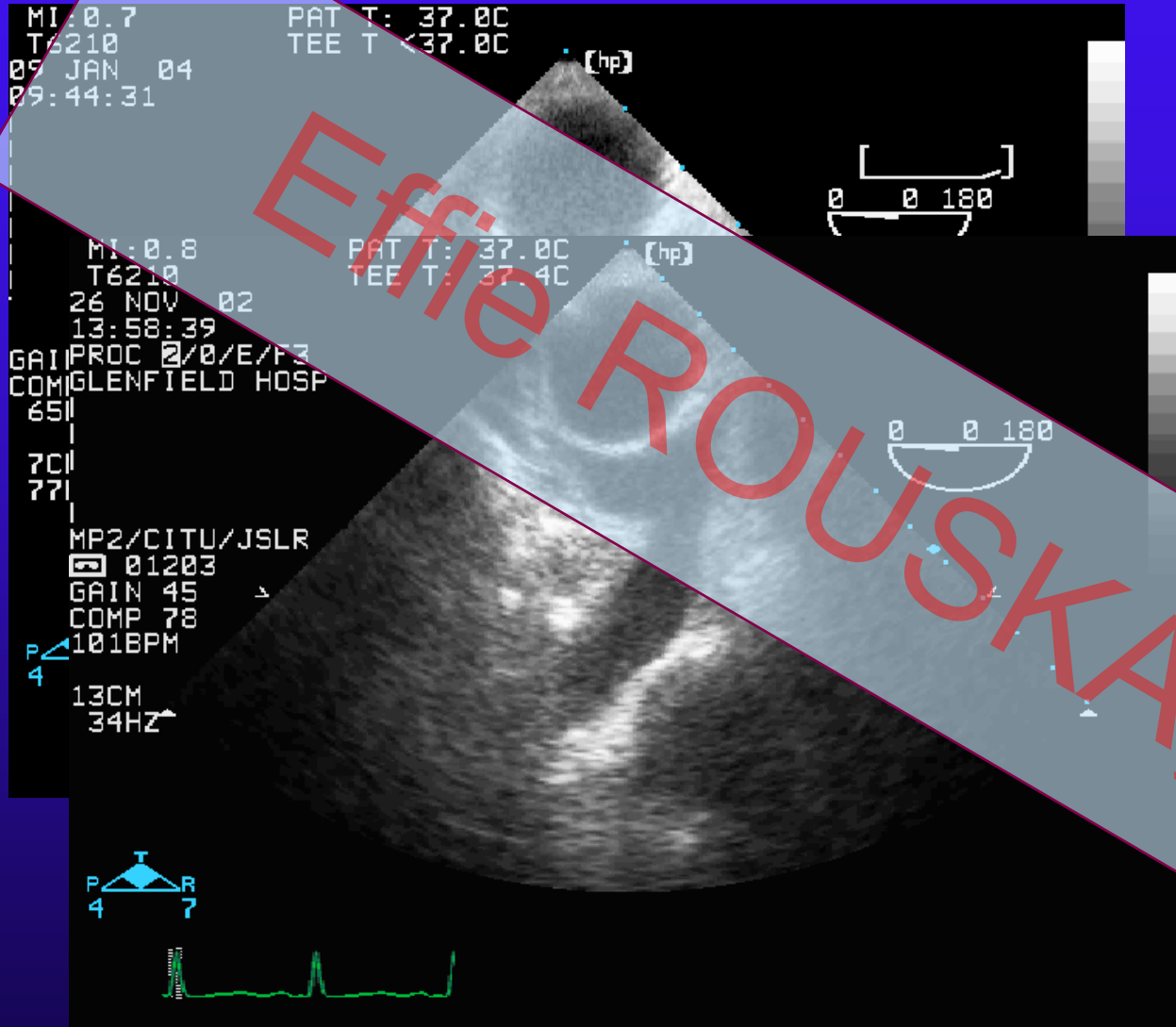
# Transgastric RV inflow



# Deep transgastric LAX

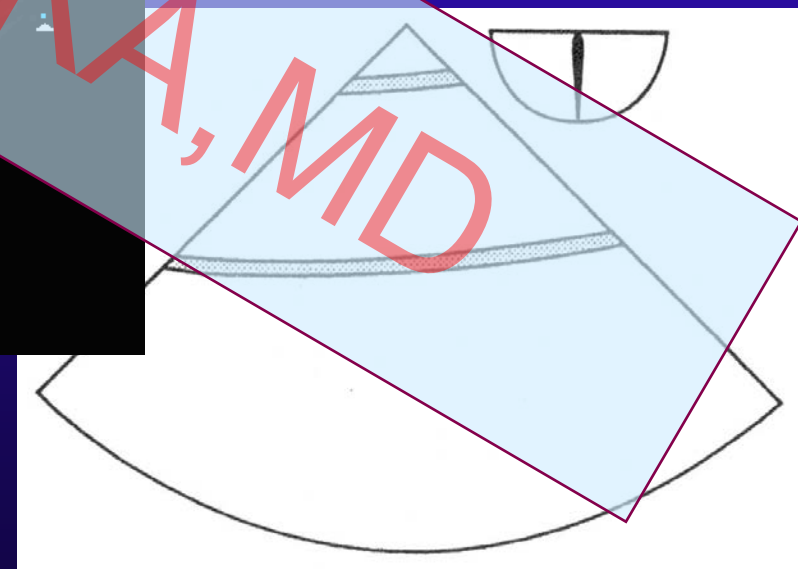
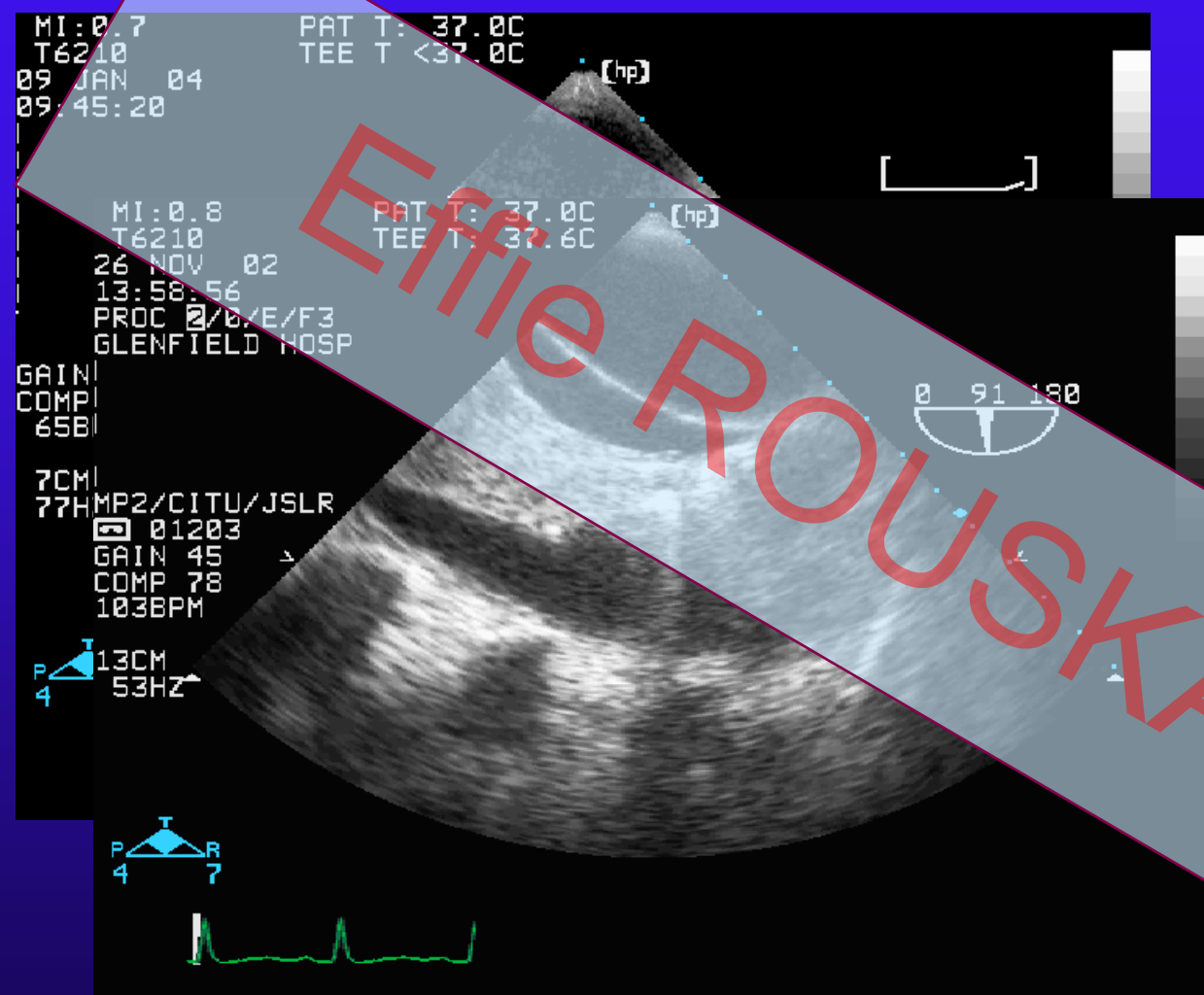


# Descending aorta SAX

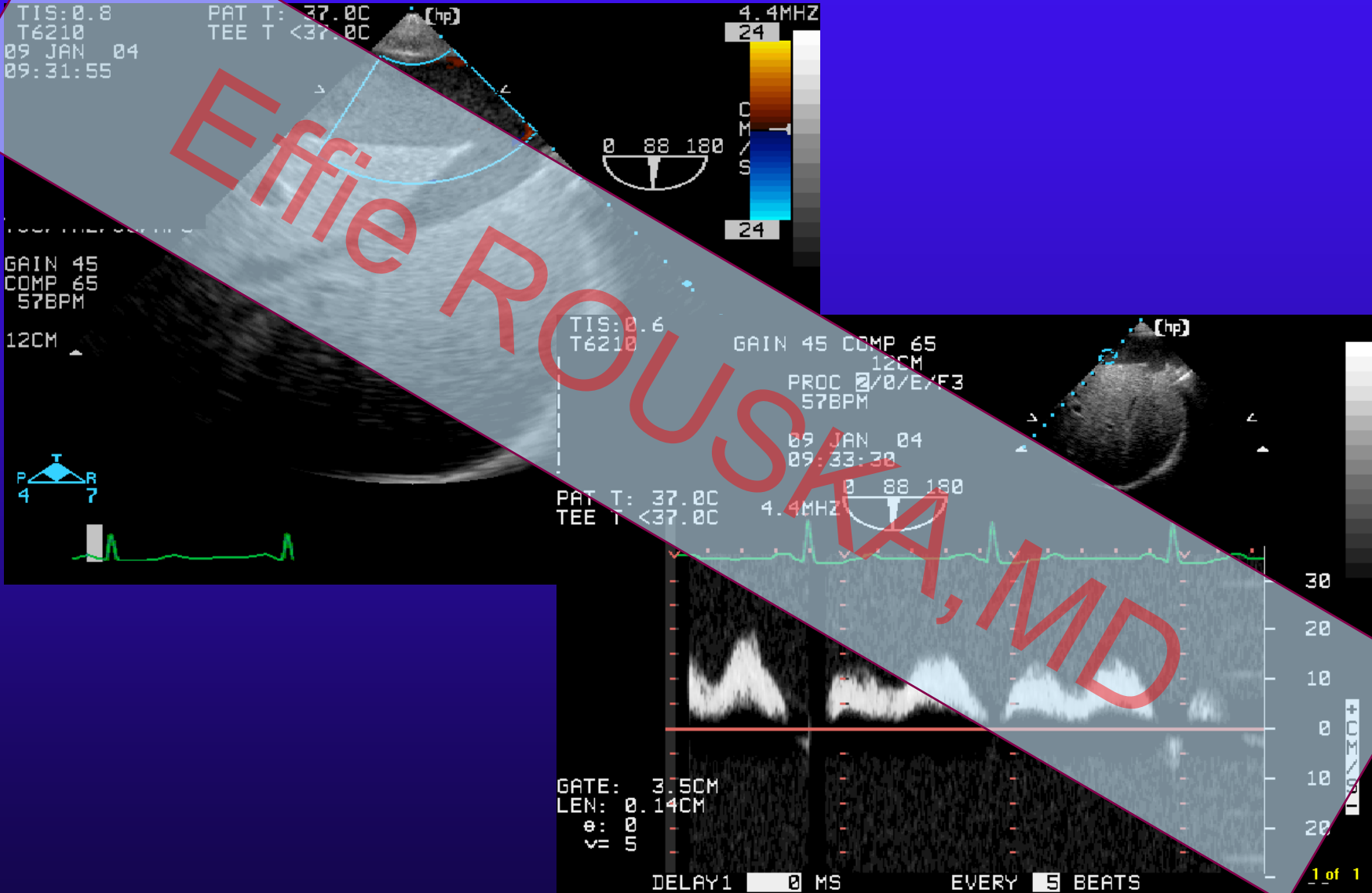


Effie ROUSKA, MD

# Descending aorta LAX



# Another useful view



# Complications

- direct trauma
- indirect effects
- inaccurate information
- distraction from patient care
- contra-indications

absolute  
relative

Kallmeyer et al. The safety of intraoperative transesophageal echocardiography: a case series of 7200 cardiac surgical patients. *Anesth Analg* 2001;92:1126-30

Any Questions?

Effie ROUSKY, MD

